26-27-28 JANVIER 2022 HIGH TECH MARSEILLE

Nouvelles options dans le traitement des lésions calcifiées

GACI

Une lésion idéale pour l'athérectomie orbitale

Institut Cardio-Vasculaire
GROUPE HOSPITALIER MUTUALISTE DE GRENOBLE

Jacques Monségu
Institut Cardio Vasculaire de Grenoble

Conflits d’intérêts

Consulting : Terumo

L'athérectomie orbitale
Comment ça marche ?

Double mécanisme d'action

Athérectomie orbitale

Couronne sertie de diamants

Force centrifuge F = $\frac{m.V^2}{R}$

Action elliptique bi-directionnelle

>> réduction plaque Ca++

2 vitesses: 80 000 & 120 000 T/mn

2.5 – 4 mm





L'athérectomie orbitale
Comment ça marche ?

Modification de la plaque

Forces pulsatiles

Action en profondeur

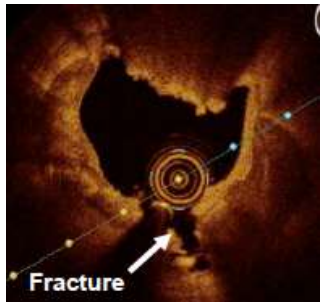

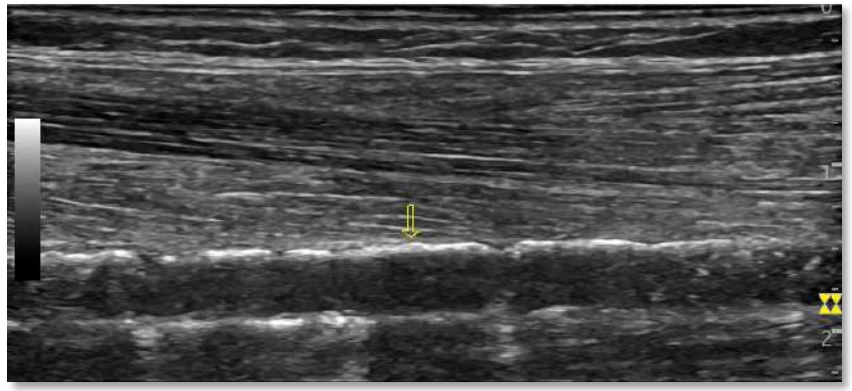

Avant athérectomie Orbitale

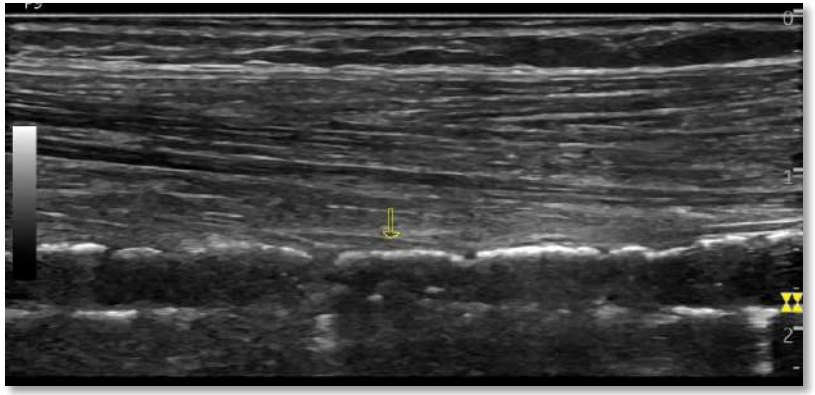

Après athérectomie Orbitale

L'athérectomie orbitale
Comment ça marche ?

Athérectomie rotationnelle

Athérectomie orbitale



Tube de verre droit de 2 mm
Athérectomie concentrique unidirectionnelle.
Action distale

Tube plastique courbe de 2 mm
Action distale excentrée sur le bord externe

Tube de verre droit de 2 mm
Athérectomie excentrique bidirectionnelle.
Action circonférentielle

Tube plastique courbe de 2 mm
Action toujours circonférentielle sur les bords externe et interne

Les composants

Le guide: ViperWire Advance

	Core Wire	Support Coil	Tip	Coating	Spring Tip Load	Dimensions
ViperWire Advance™ with Flex Tip First and only Nitinol-core coronary atherectomy wire Designed for reduced wire bias and kink resistance	Nitinol	Stainless Steel	Platinum / Tungsten	Silicone	1.0 gf	

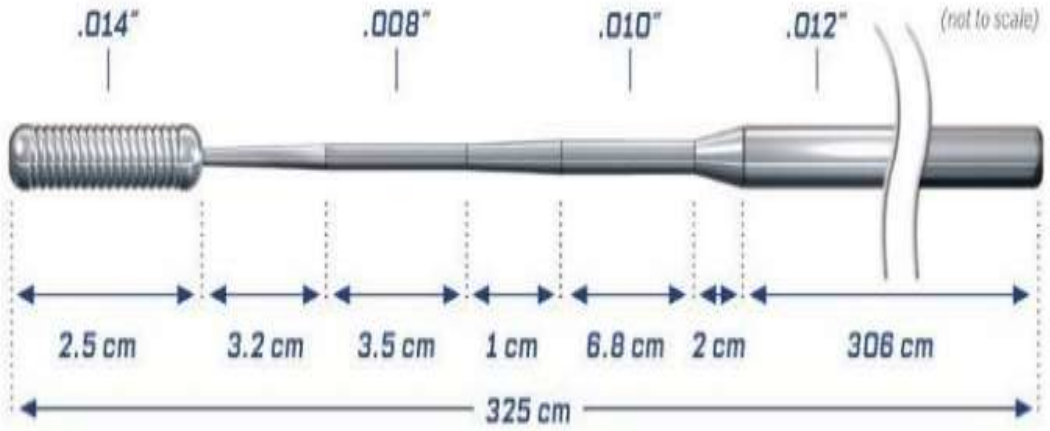

Le système Orbital et sa couronne de 1.25 mm

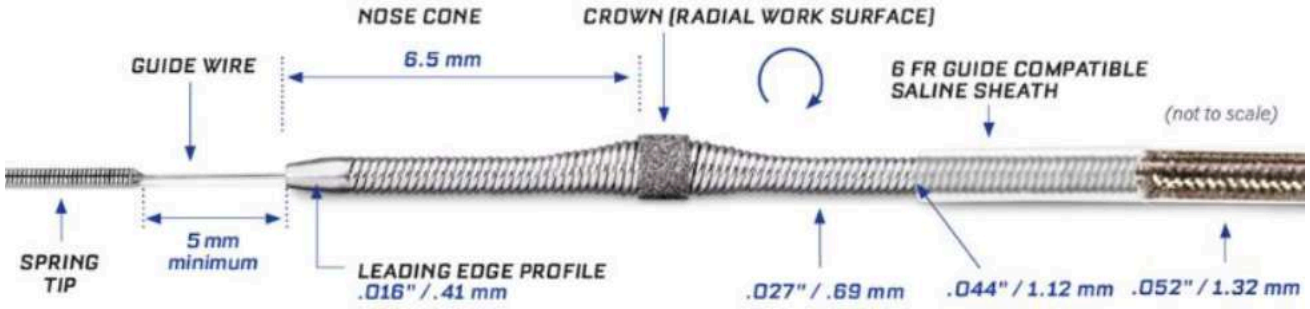

La technique

Guiding 6 Fr

Positionnement du guide en distalité

Avancement de la couronne et relâchement de la tension

Ponçage lent 1mm/sec

Vitesse lente +/- vitesse rapide

Run de 30 sec / période de repos

5 mn max

Retrait en GlideAssist

Evaluation post-athérectomie

Cas clinique

Homme de 80 ans

FDR

- Hypertension
- Coronaropathie familiale

Angor d'effort class III CCS

ECG: T négatives antérieur

Angiographie

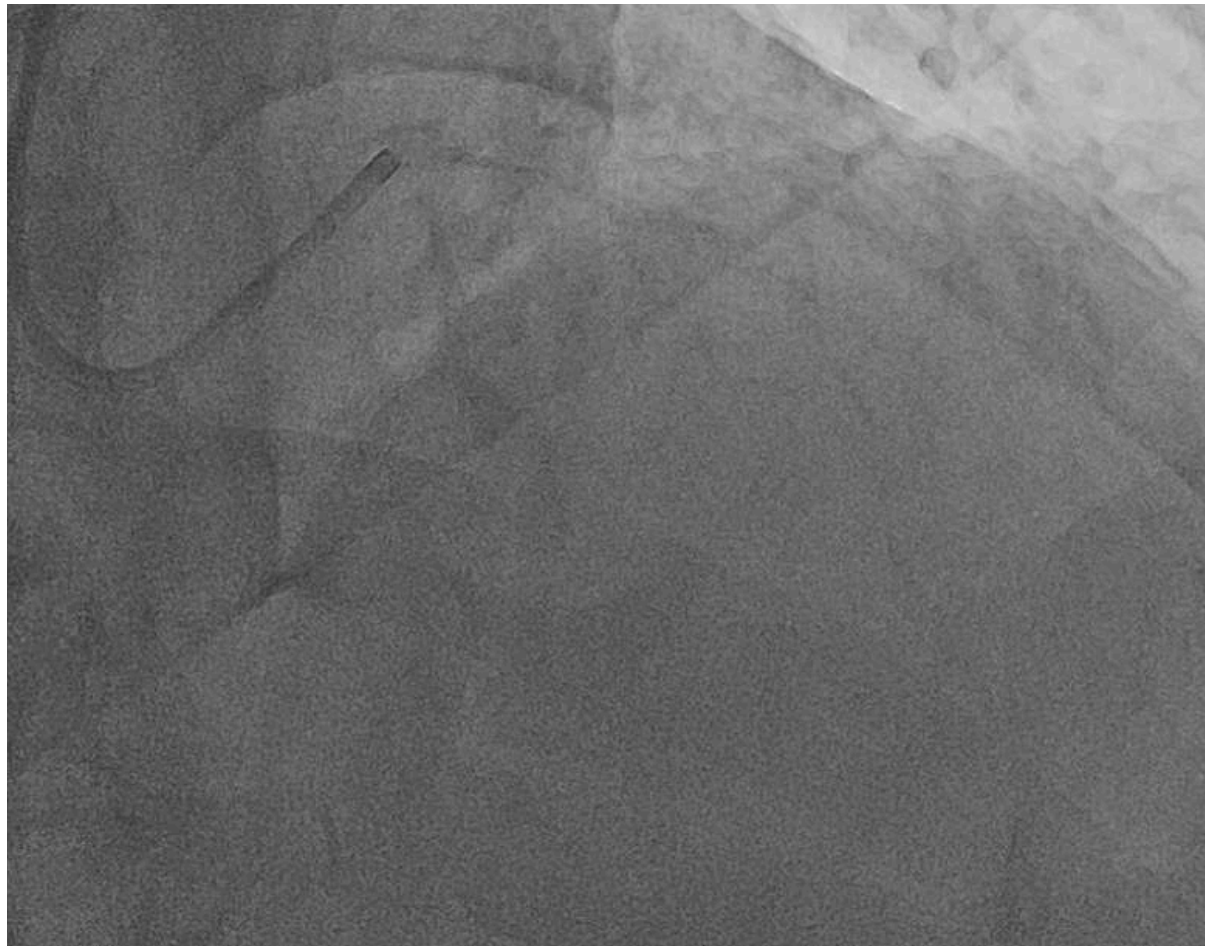

Procédure Orbitale

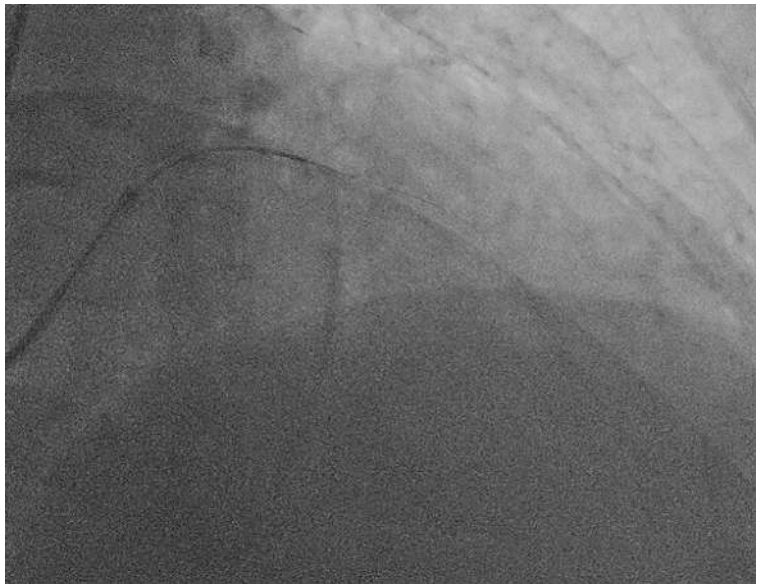

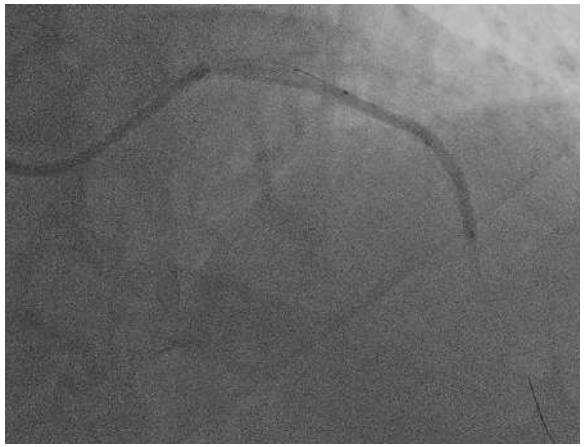

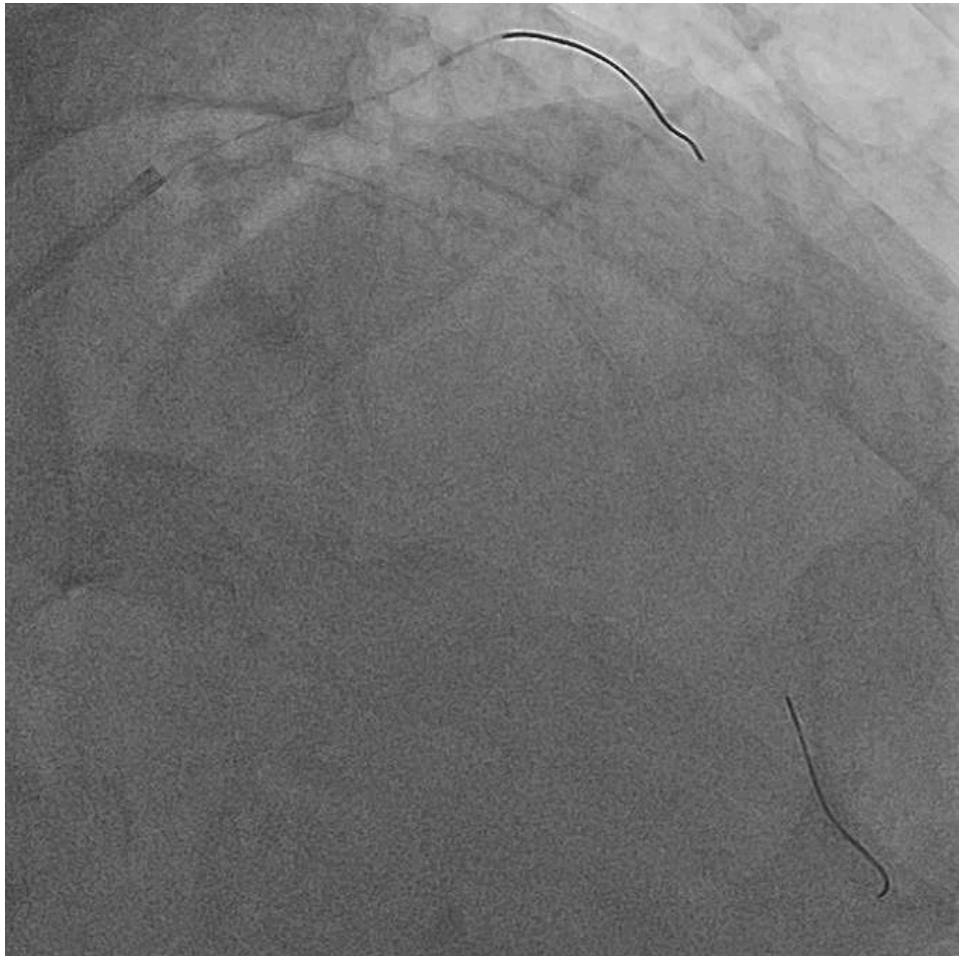

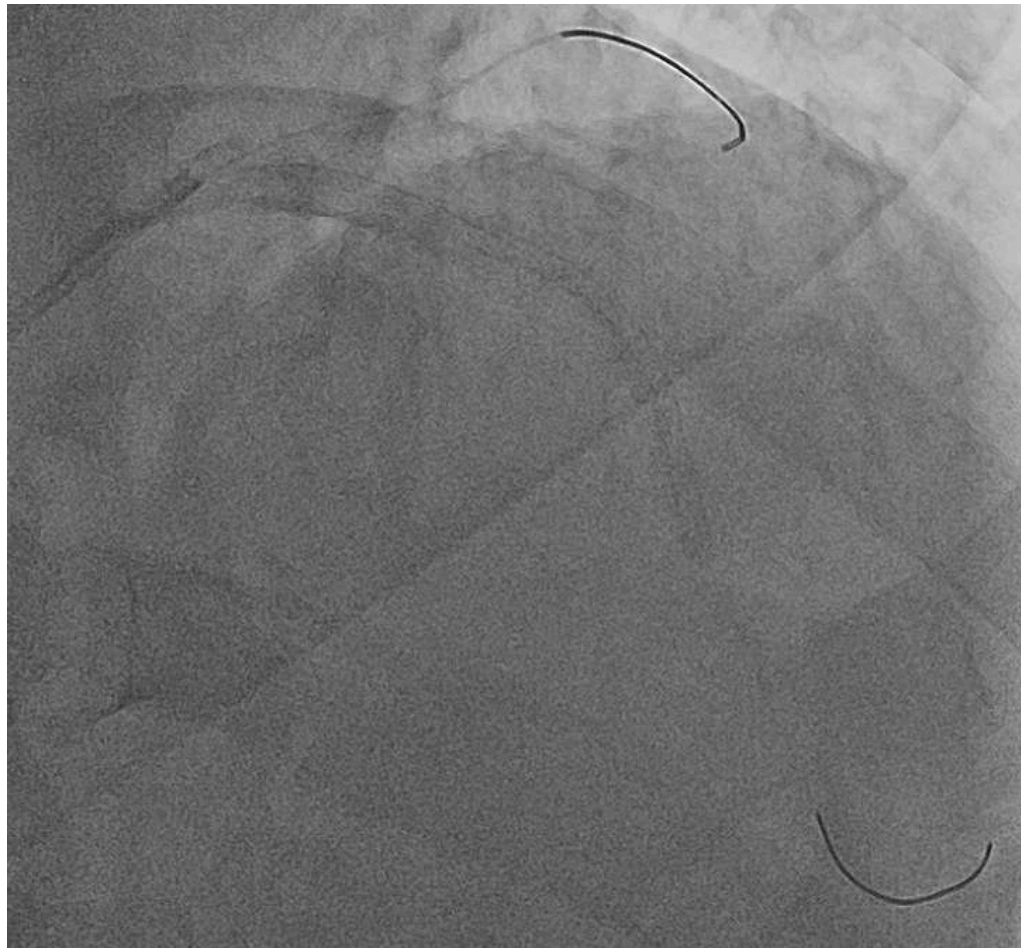

Stent 2.75 x 44 mm

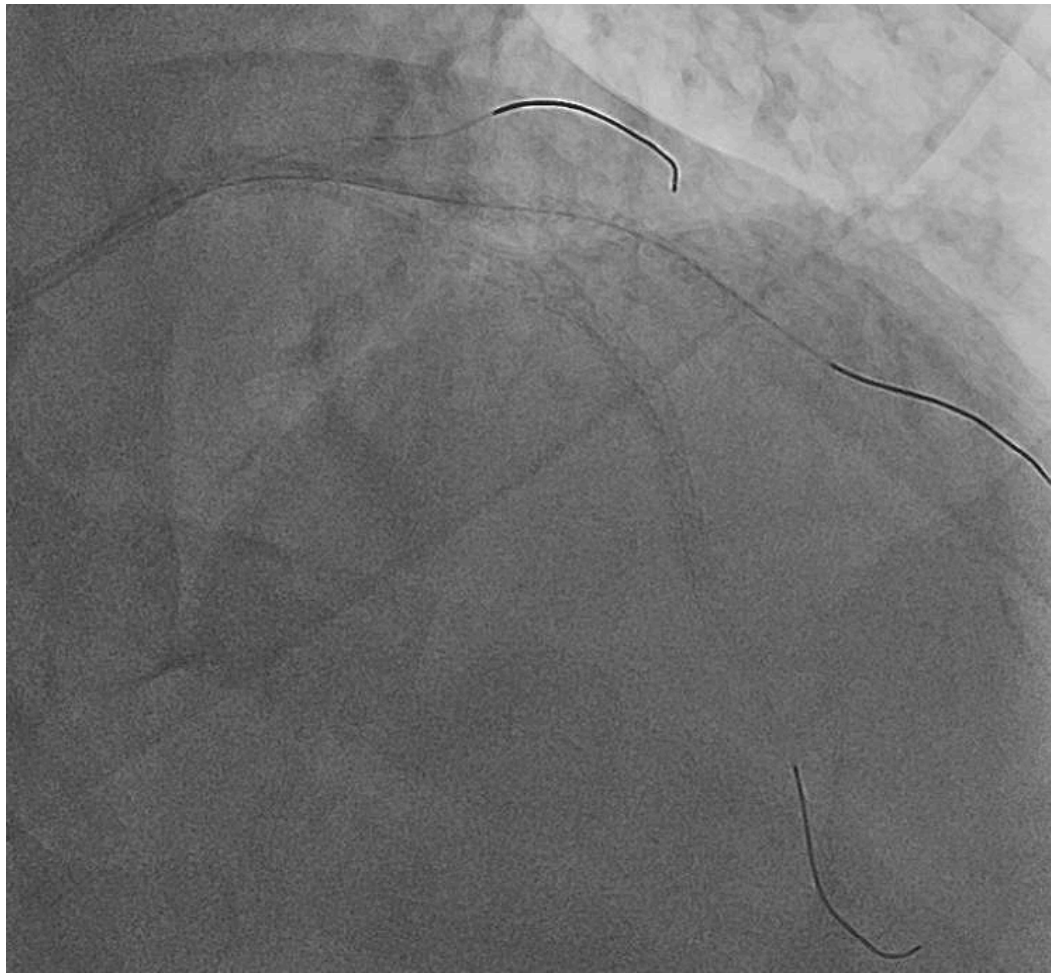

Stent 2.25 x 36 mm

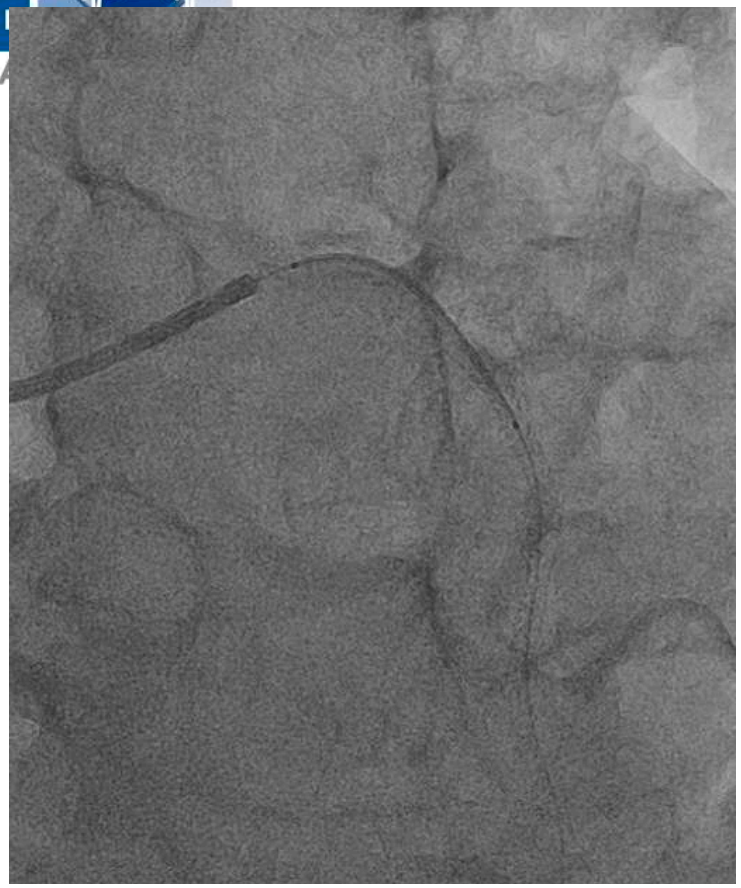

Stent 3.0 x 36 mm

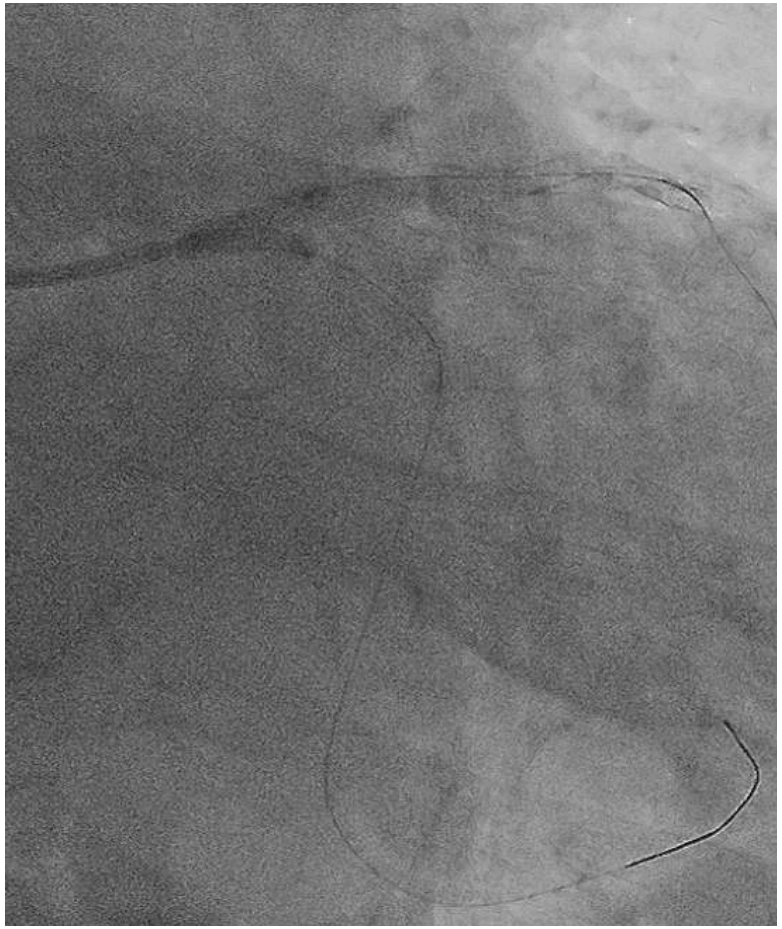

Kissing

POT

Résultat final

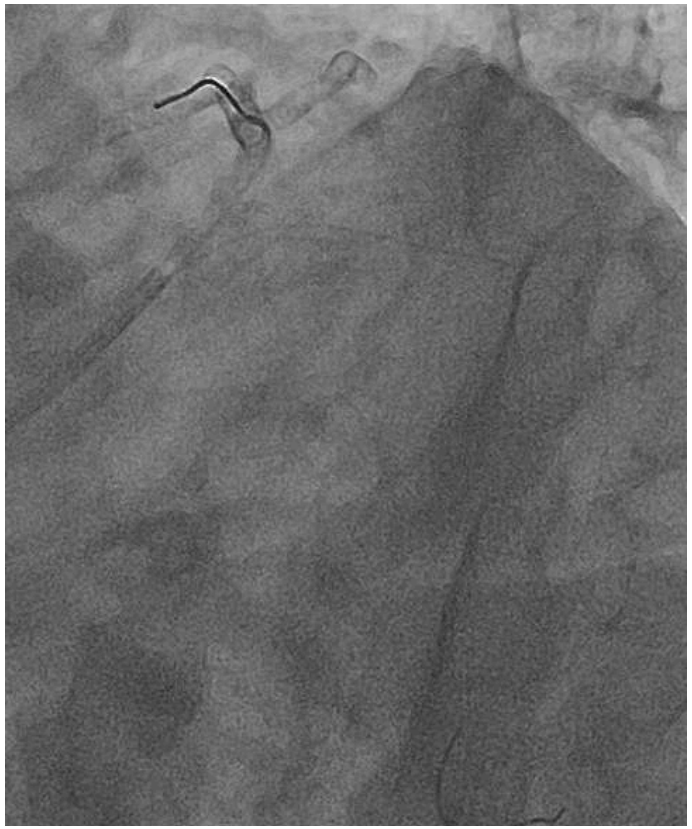

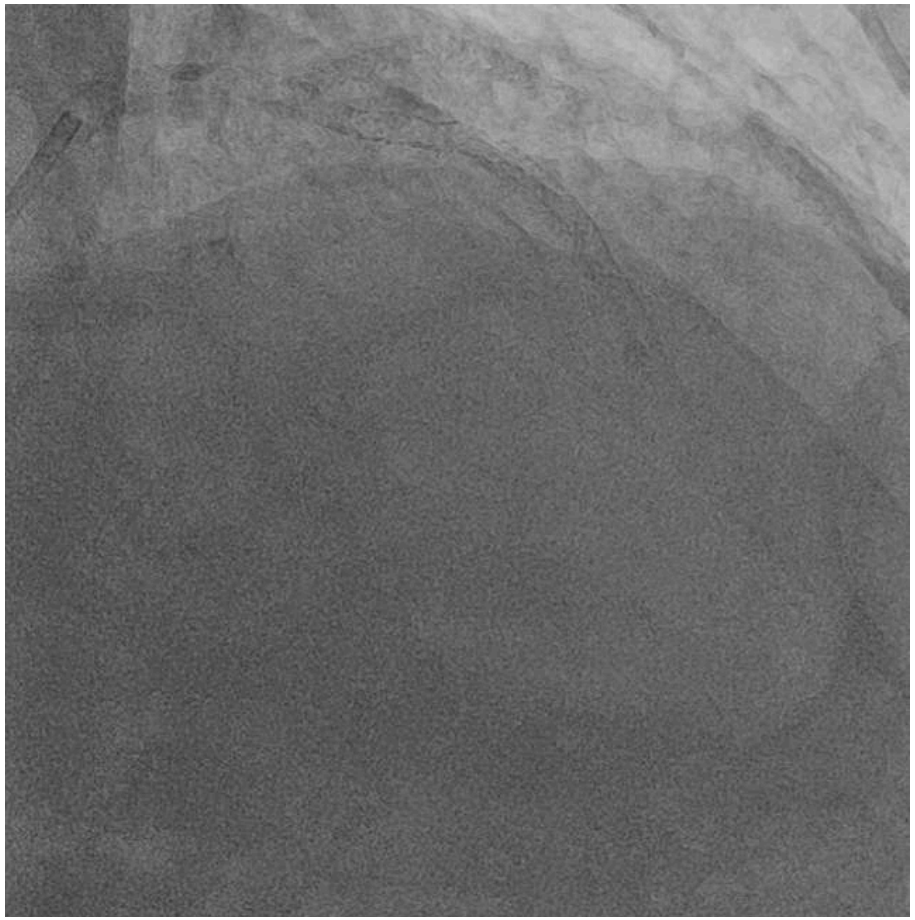

26-27-28 JANVIER 2022 HIGH TECH MARSEILLE

Mais aussi…

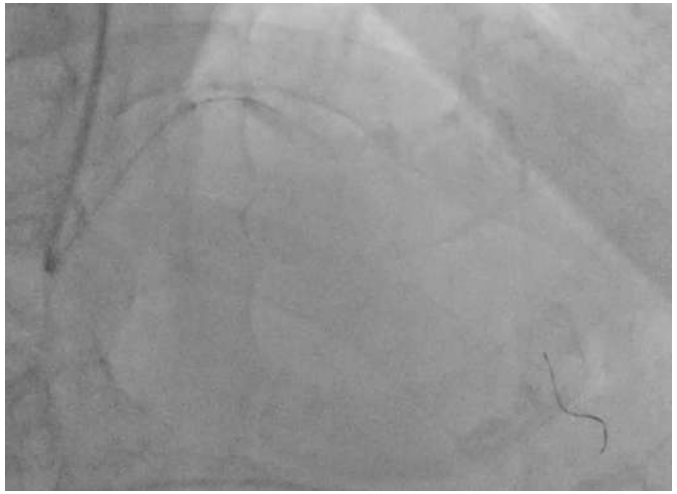

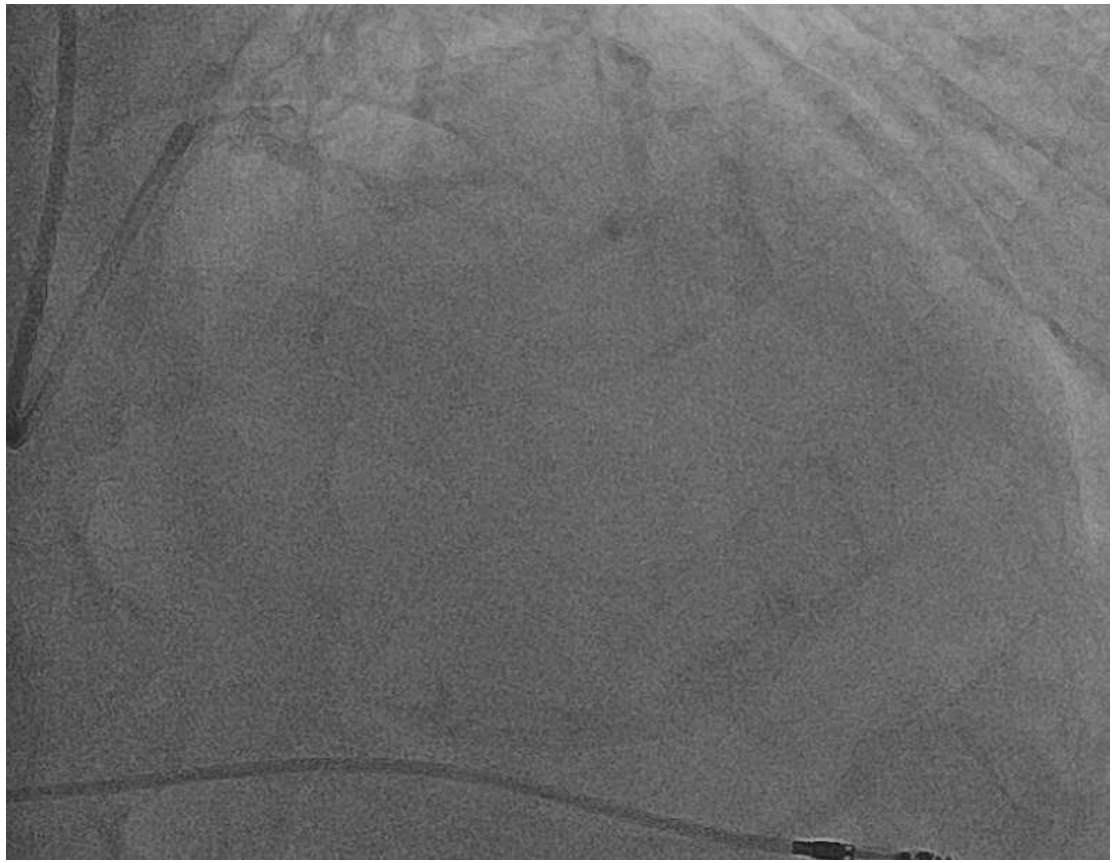

26-27-28 JANVIER 2022 HIGH TECH MARSEILLE

Mais aussi…

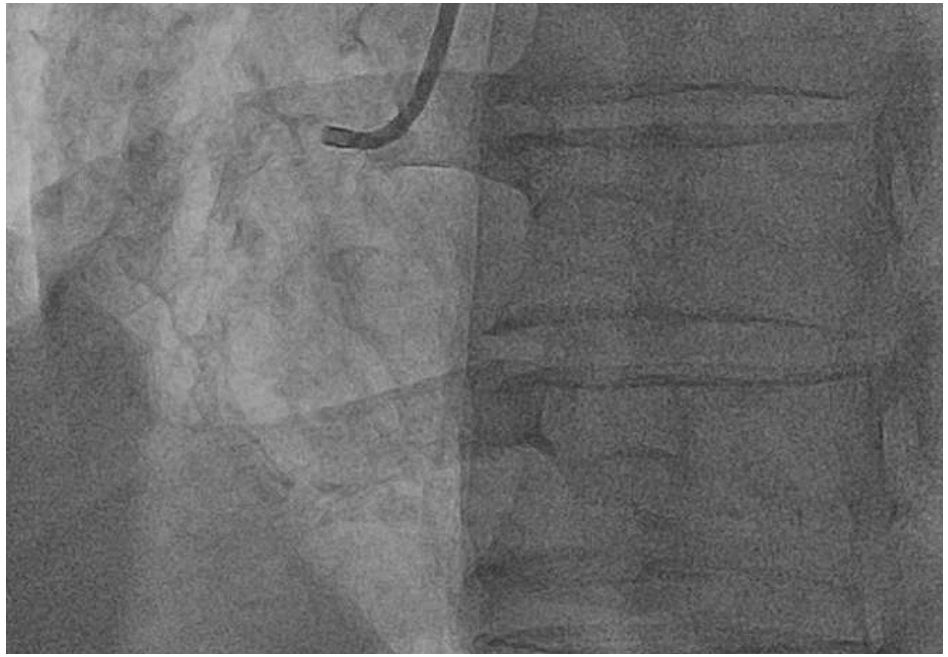

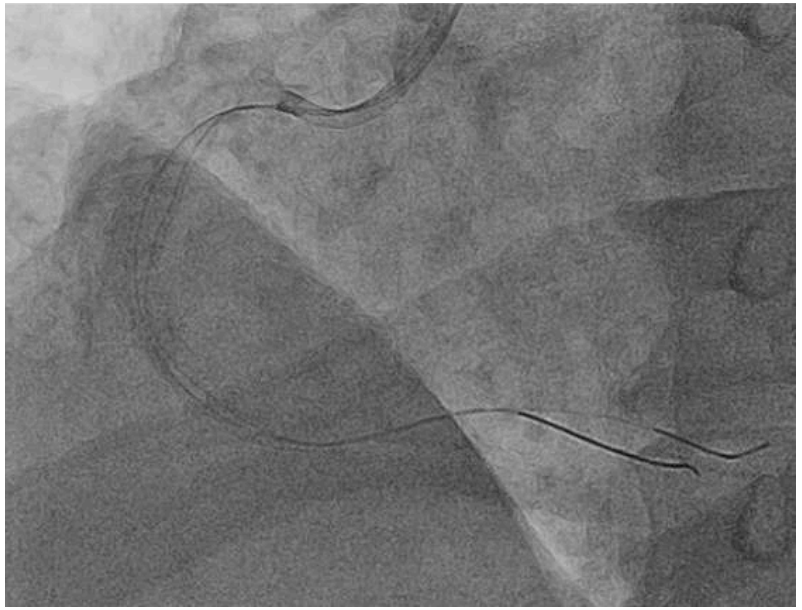

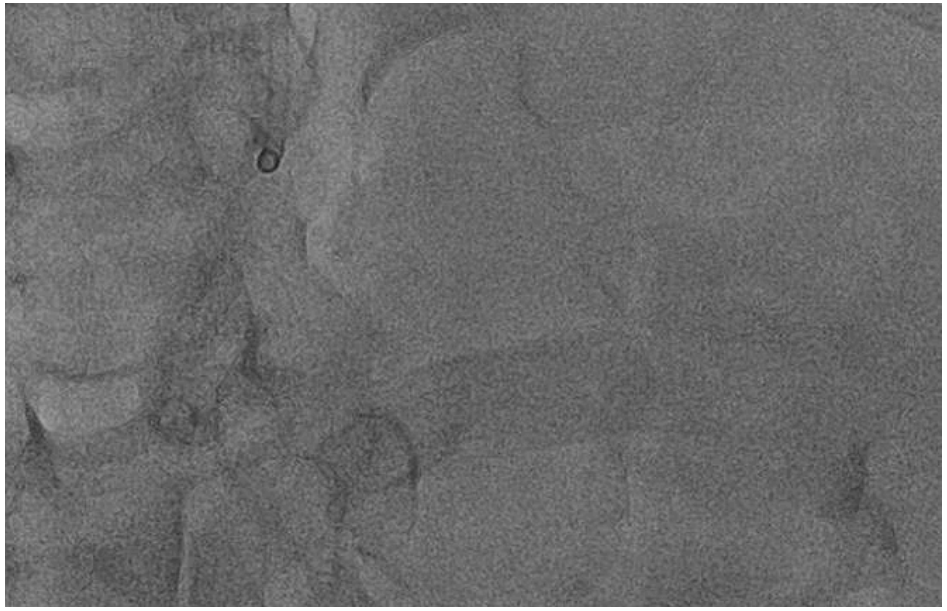

26-27-28 JANVIER 2022 HIGH TECH MARSEILLE

Mais aussi…

ORBIT II: Sécurité et efficacité

30 Day MACE Rate Components:

MI (CK-MB > 3x ULN):	9.7%
Non Q-wave	8.8%
Q-wave	0.9%
TVR/TLR:	1.4%
Cardiac Death:	0.2%

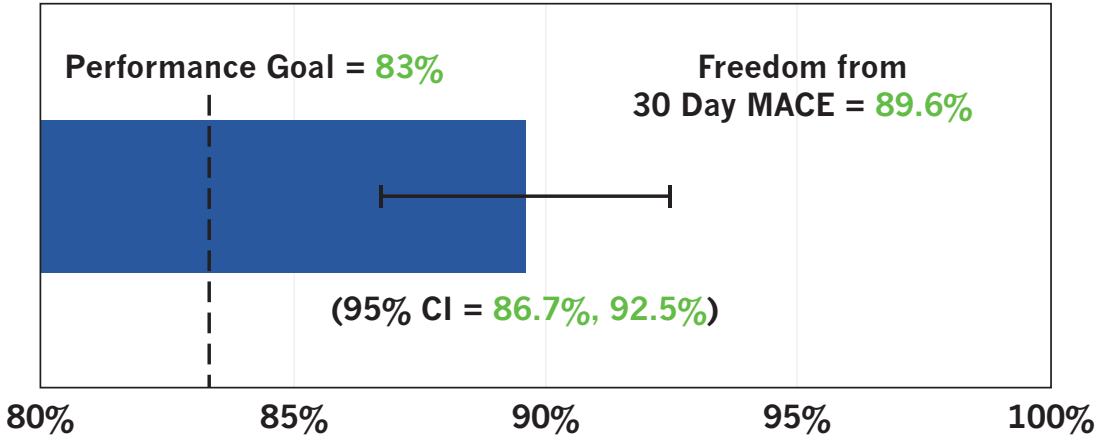

Procedural Success Components:

Successful Stent delivered: 97.7%

Less than 50% residual stenosis: 98.6%

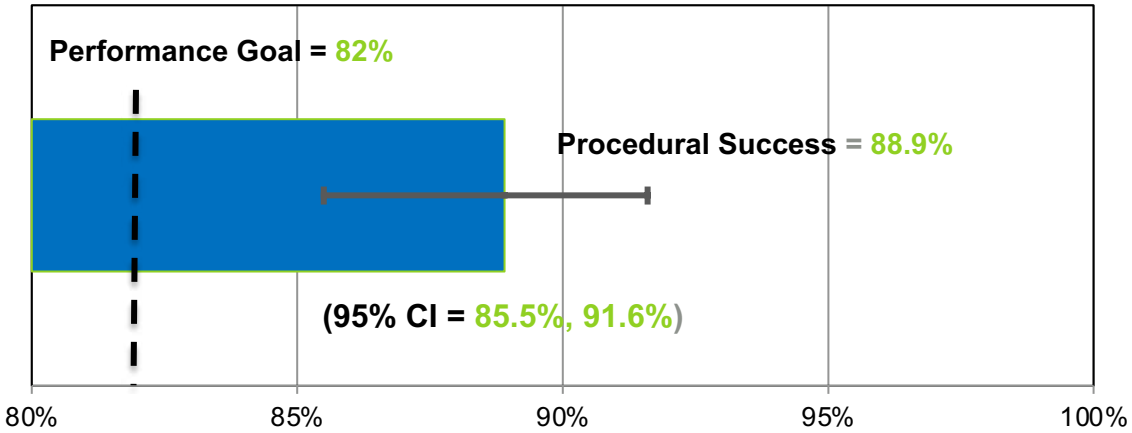

1. *Chambers JW, et al. JACC Cardiovasc Interv. 2014;7:510-8*
2. *Lee MS, et al. Cardiovasc Revasc Med. 2018;19:498-502*

ORBIT II: Les complications per-procédures

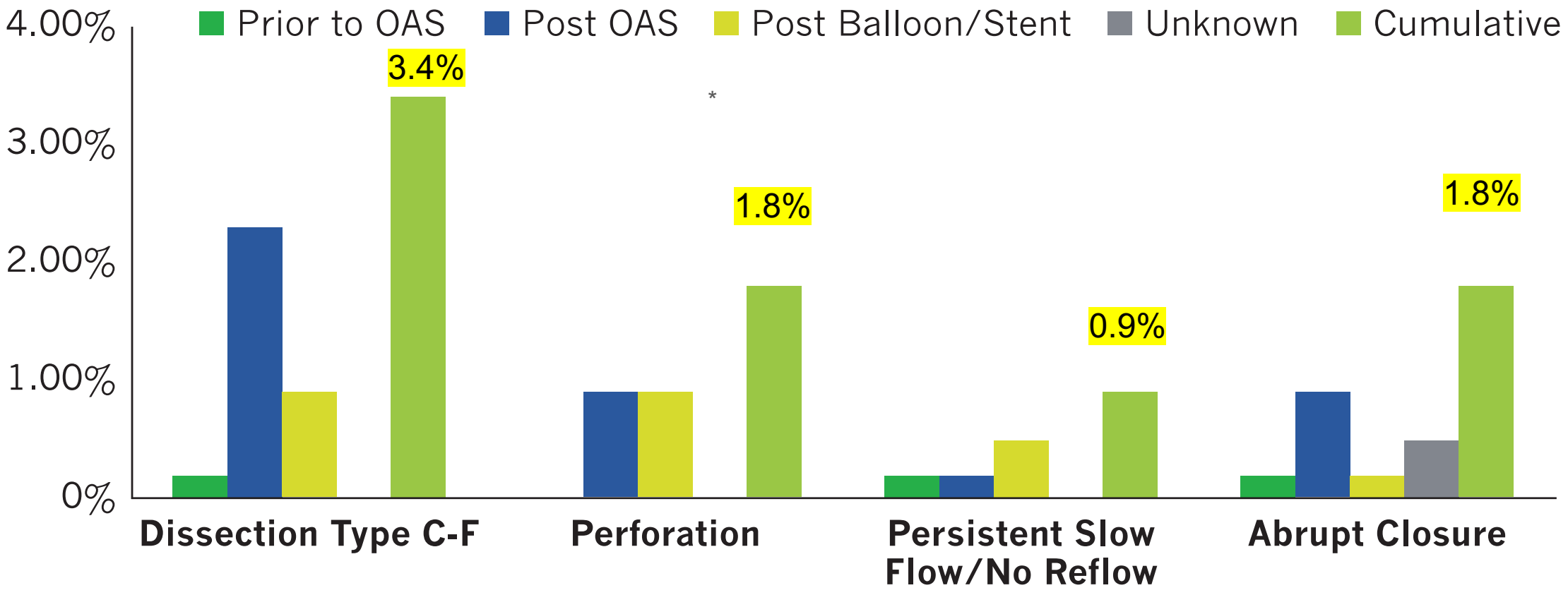

Chambers JW, et al. JACC Cardiovasc Interv. 2014;7:510-8

ORBIT II: résultats à long terme

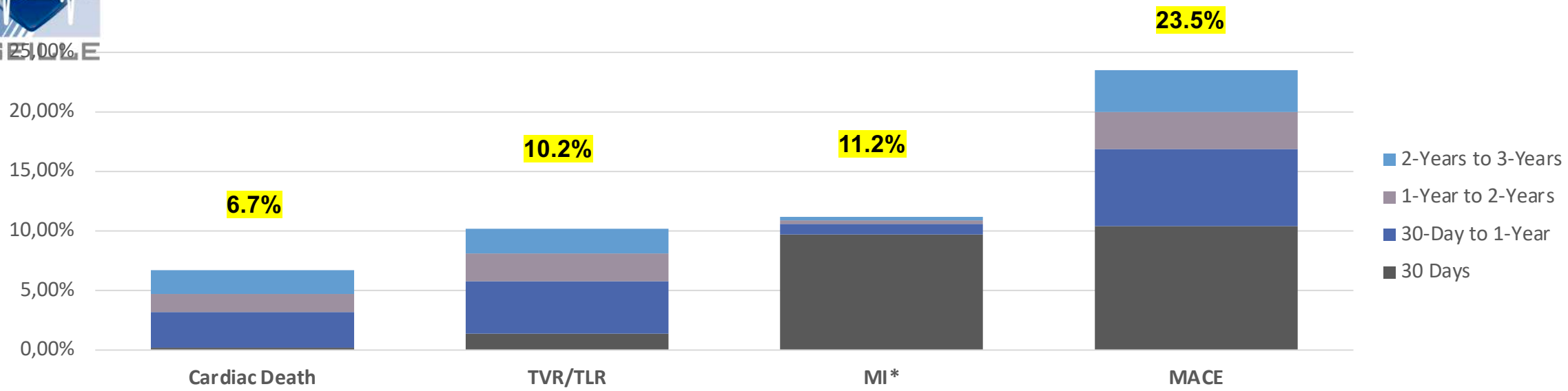

	In Hospital[1]	30 Day[2]	1 Year[2]	2 Year[2]	3 Year[2]
Revascularization					
TVR/TLR	0.7%	1.4%	5.8%	8.1%	10.2%
TLR		0.7%	4.7%	6.2%	7.8%
TVR (non-TLR)		0.7%	1.9%	2.6%	3.4%

1. *Chambers JW, et al. JACC Cardiovasc Interv. 2014;7:510-8*
2. *Lee MS, et al. Cardiovasc Revasc Med. 2017;18:261-264*

Les lésions à éviter

La coronaire unique

Le pontage

Le thrombus

La lésion avec dysfonction VG sévère

La prudence

La resténose intrastent

Les ostia coronaires

La lésion disséquée

Une lésion idéale pour l'athérectomie orbitale

Un nouvel outil >> double action

Lésion calcifiée plutôt concentrique

Plutôt longue

Sur une artère tortueuse avec des collatérales

Primo-intention, plutôt qu'en bail-out

>> vrai changement de paradigme

>> préparation optimale de la lésion avant stenting

Registre prospectif collaboratif français REFORCE