



28-30
JANVIER
2026

MARSEILLE
PALAIS DU PHARO

Une histoire de mailles

Simon BERGER, Docteur Junior
CHU Clermont-Ferrand
sberger1@chu-clermontferrand.fr



CARDIOLOGIE
• CHU •
CLERMONT
FERRAND

Mr O. 55 ans



FDRCV :

- Age
- Sexe masculin
- Dyslipidémie

Traitements : Aucun

ATCD extracardiaques :
RGO & IRC

ATCD cardiaques :

2023 :

Cardiopathie ischémique
absence de CRH

Mr O. 55 ans

Histoire de la maladie :

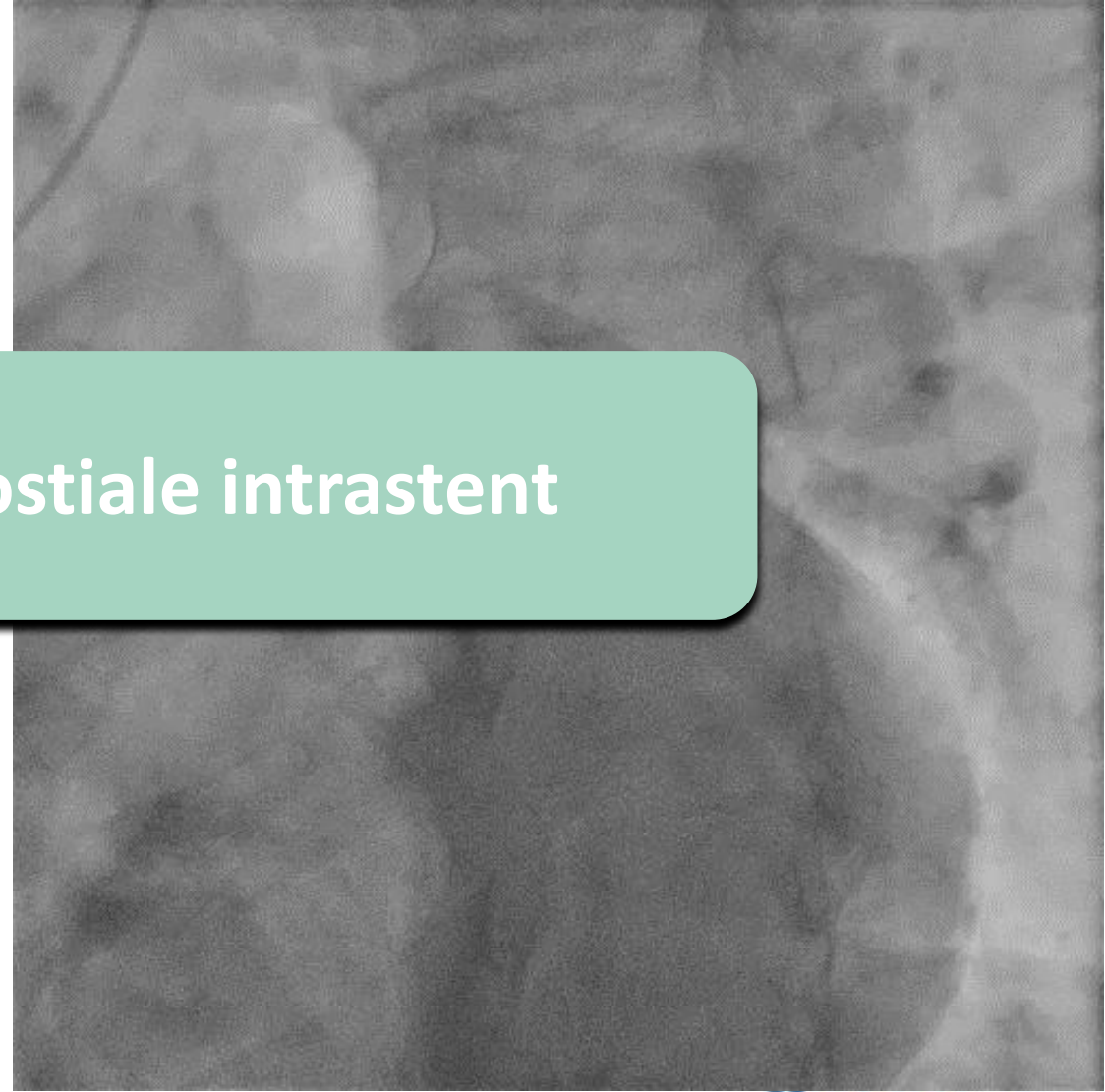
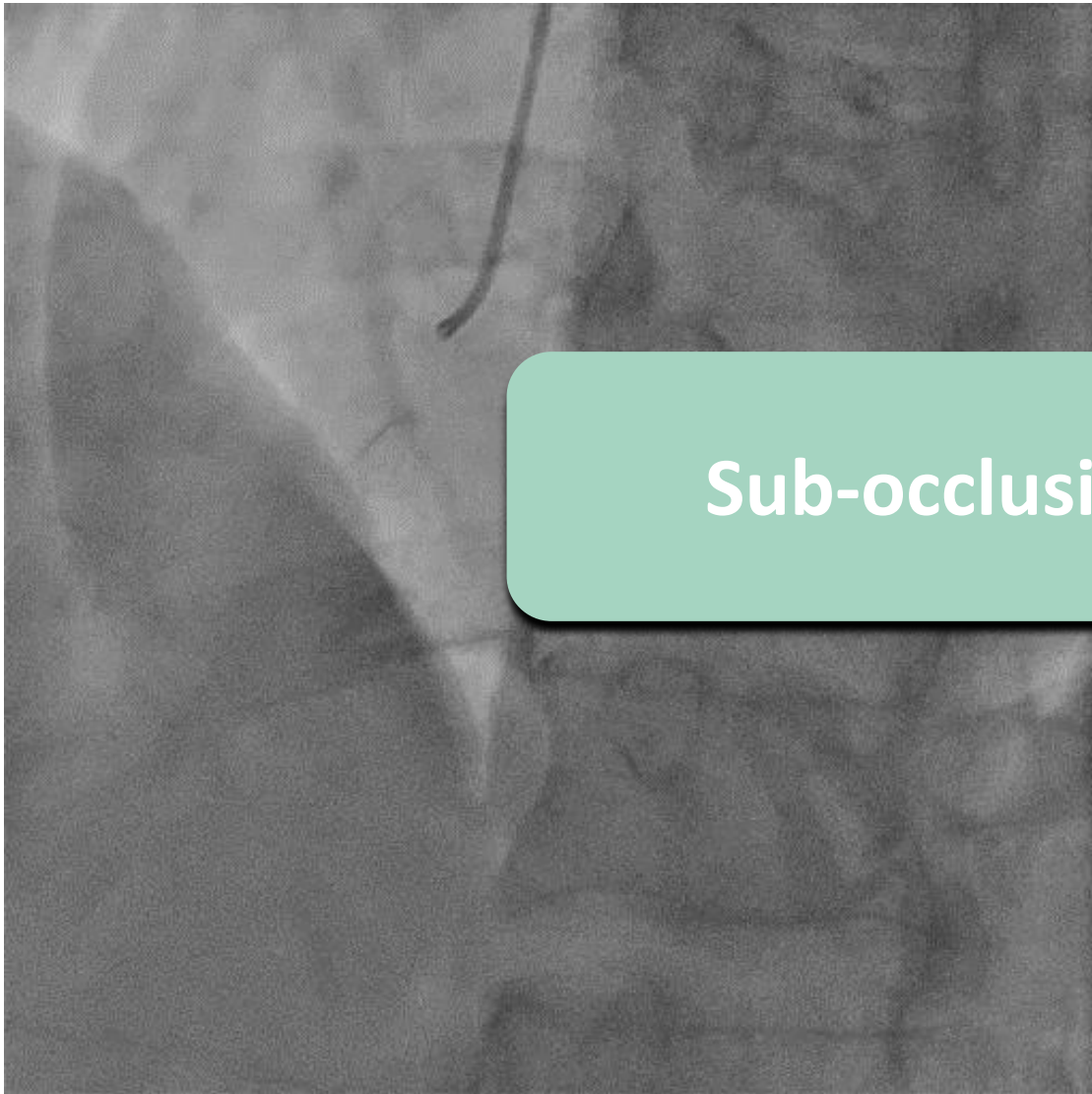
Mai 2025 :

Arrêt KARDEGIC et du BRILIQUE

Angor d'effort

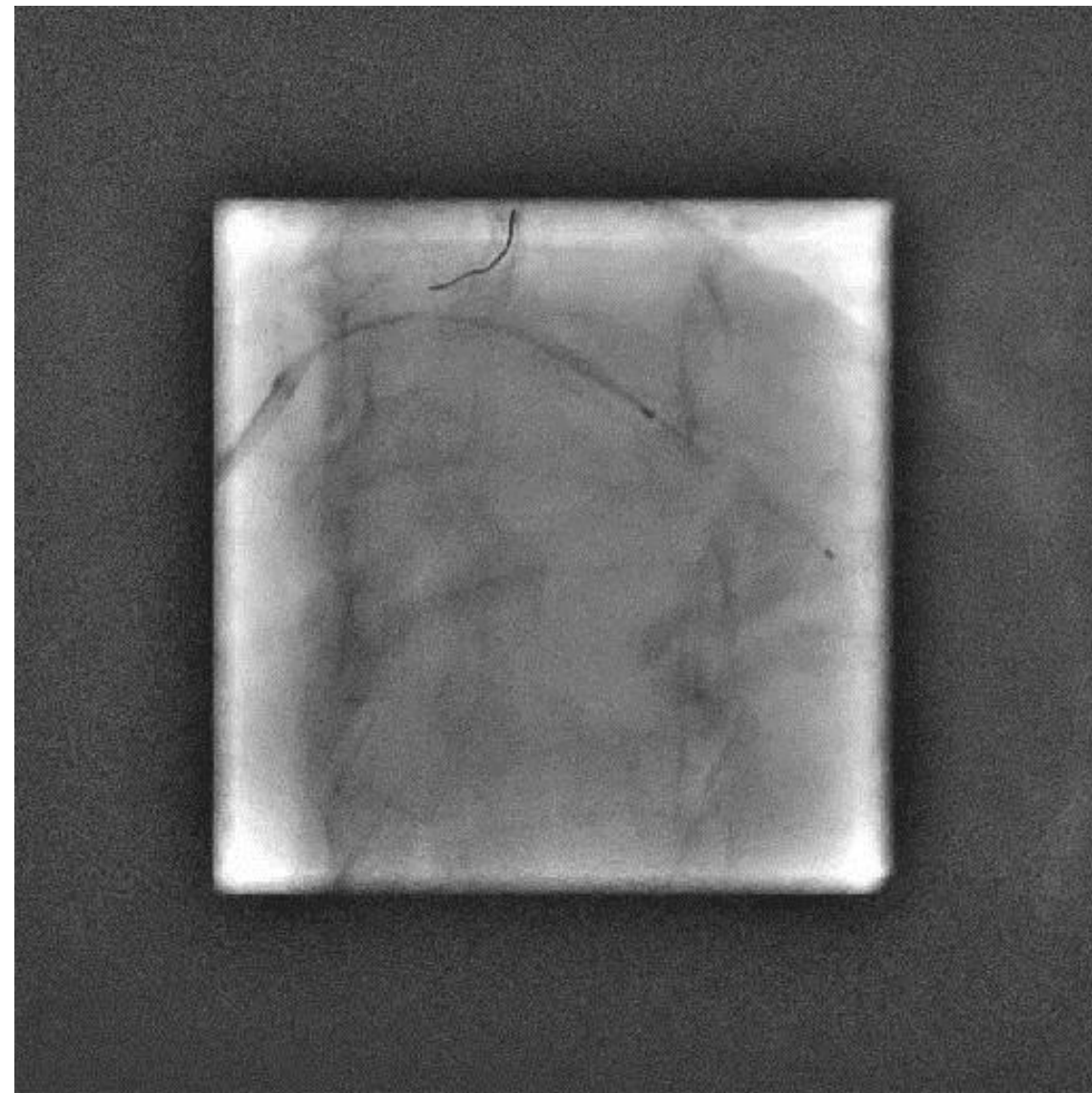

14/05/2025 prise en charge en USIC pour NSTEMI

Coronarographie



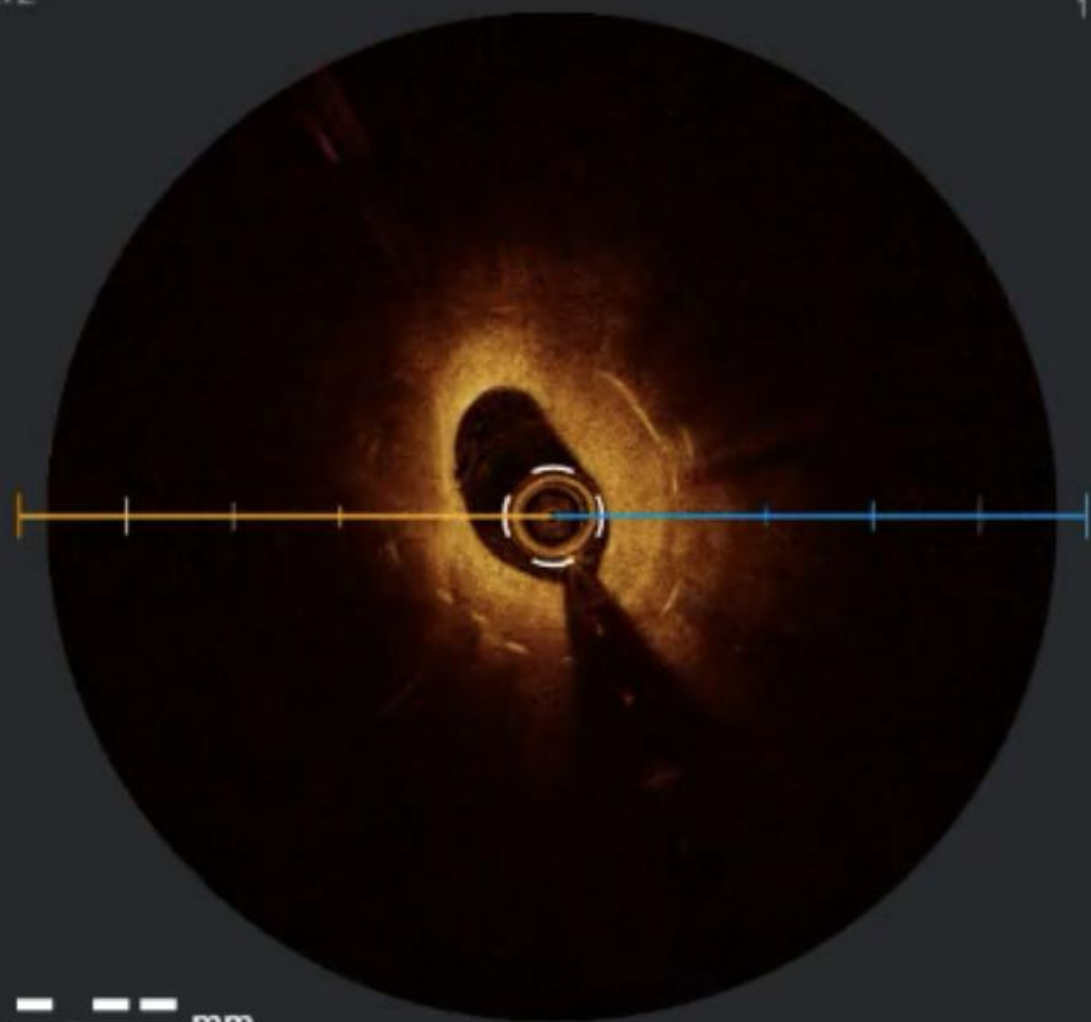
Sub-occlusion Cx ostiale intrastent

Angioplastie



F:272

1 mm



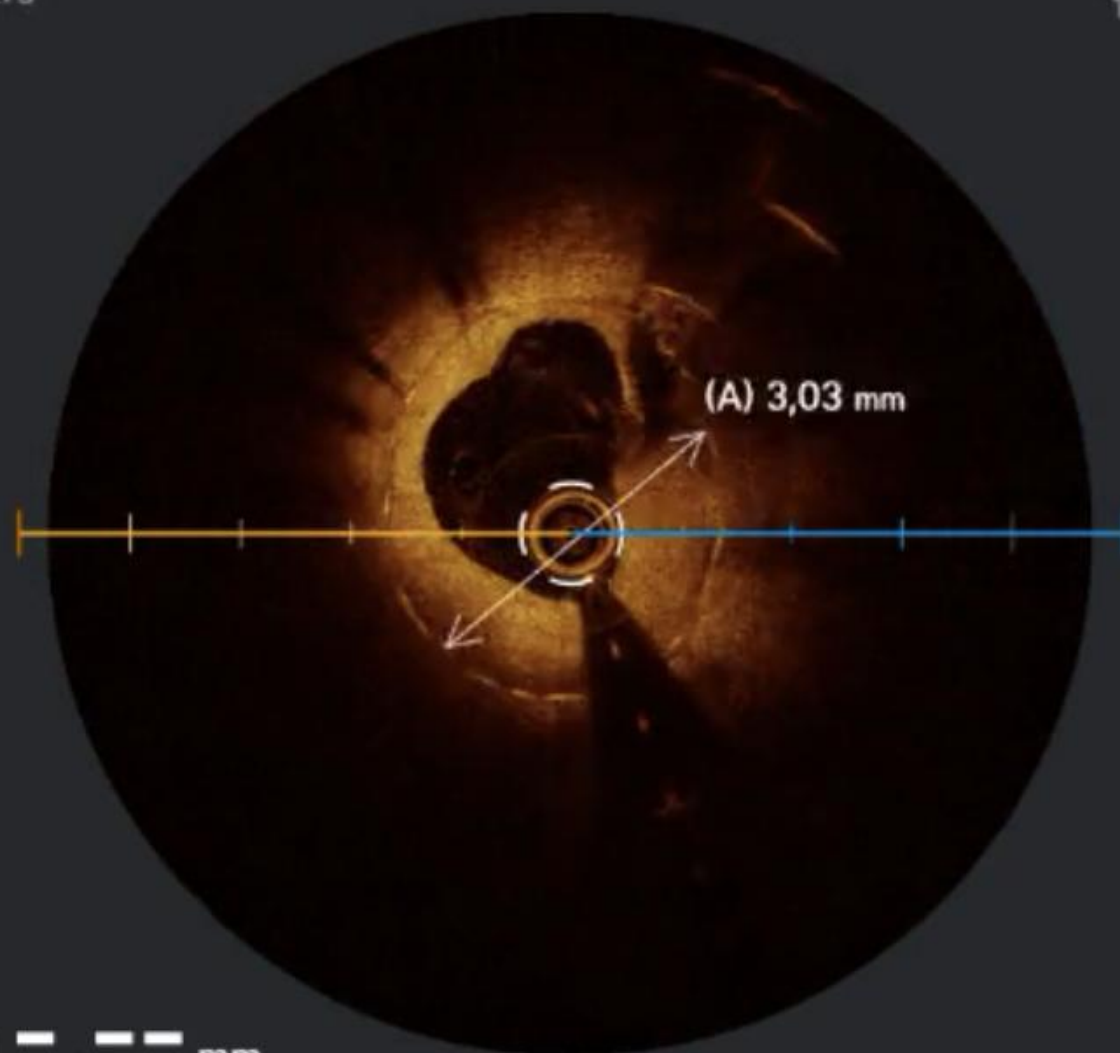
E —, --- mm

L 1,52 mm

LA 1,87 mm²

F:278

1 mm

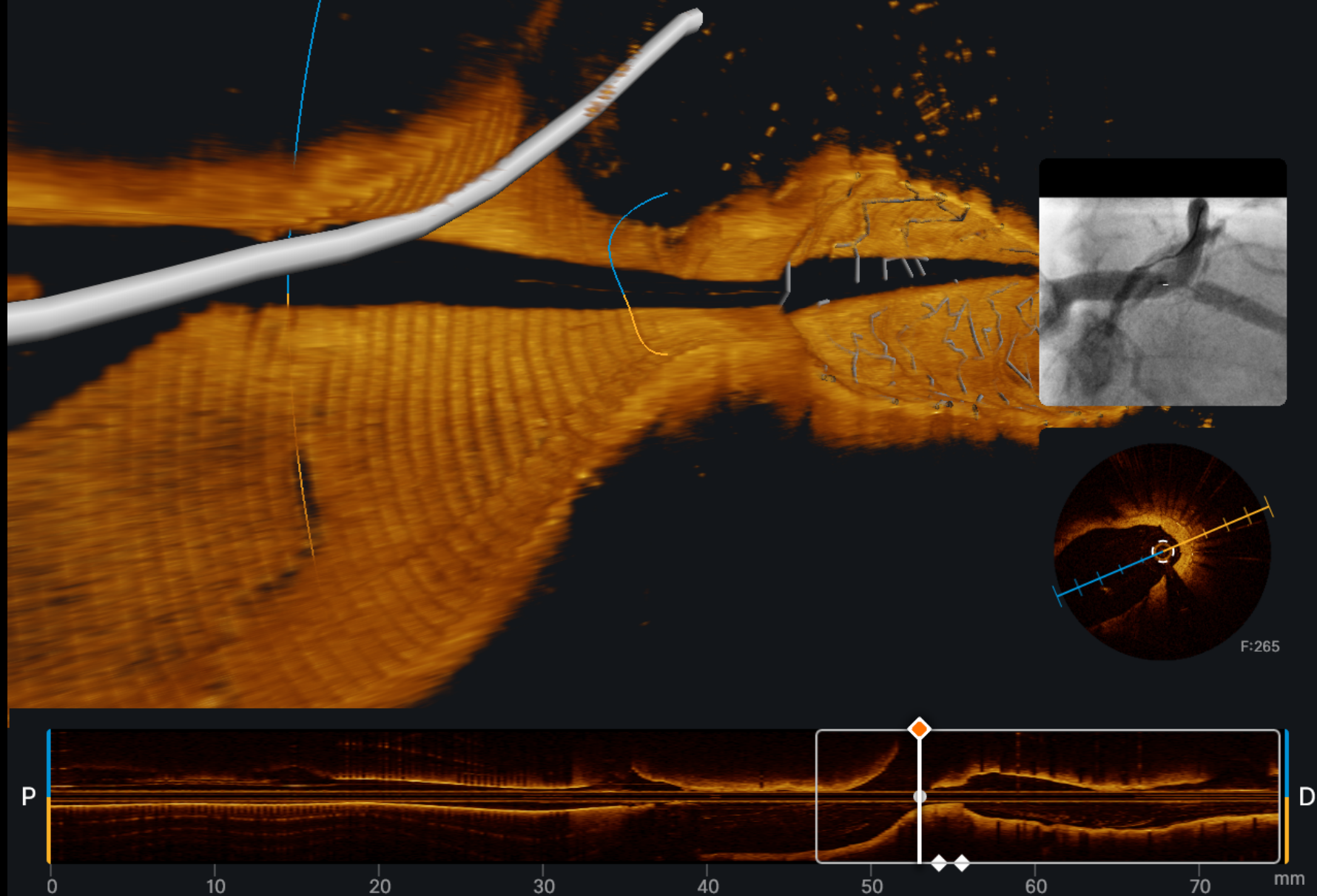


E —, --- mm

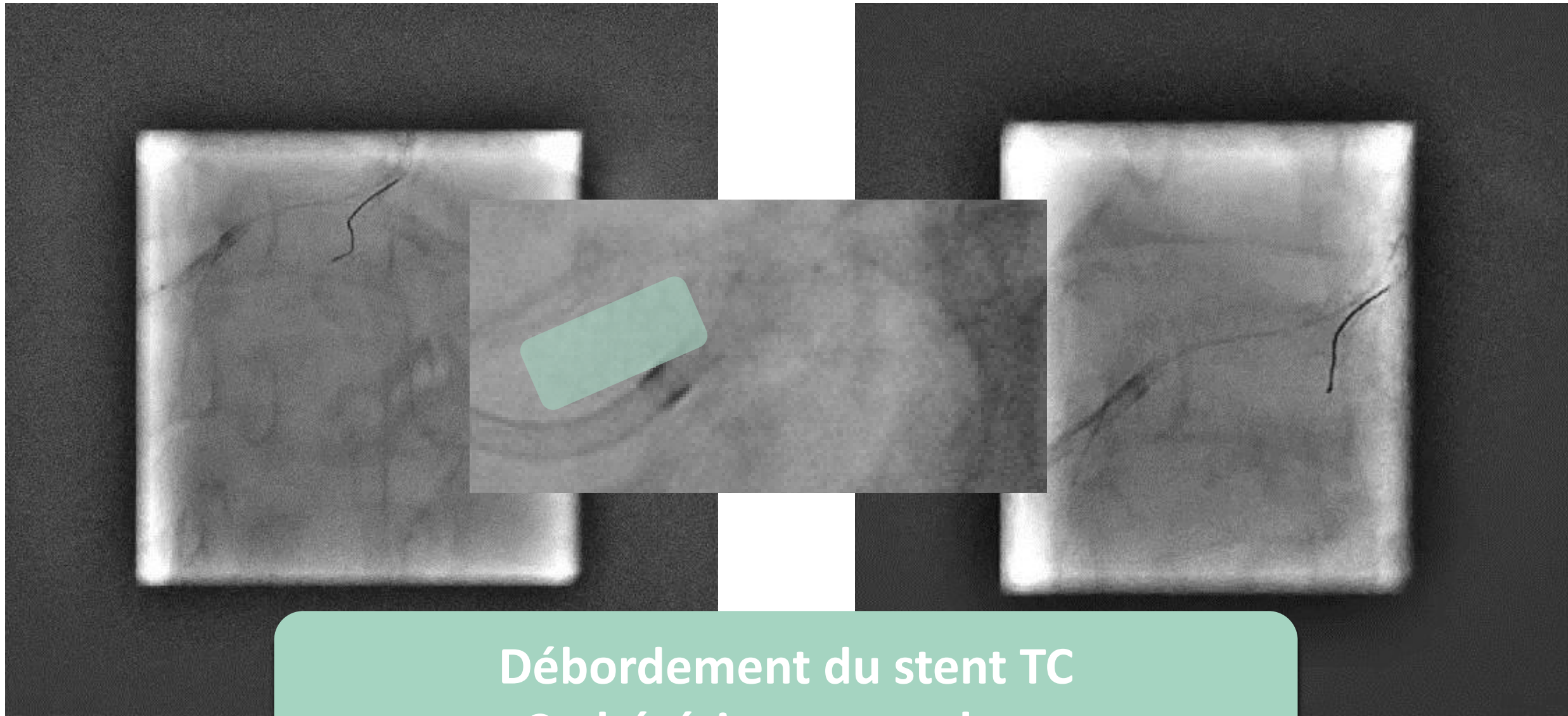
L 2,15 mm

LA 3,69 mm²

Vue en 3D de la bifurcation

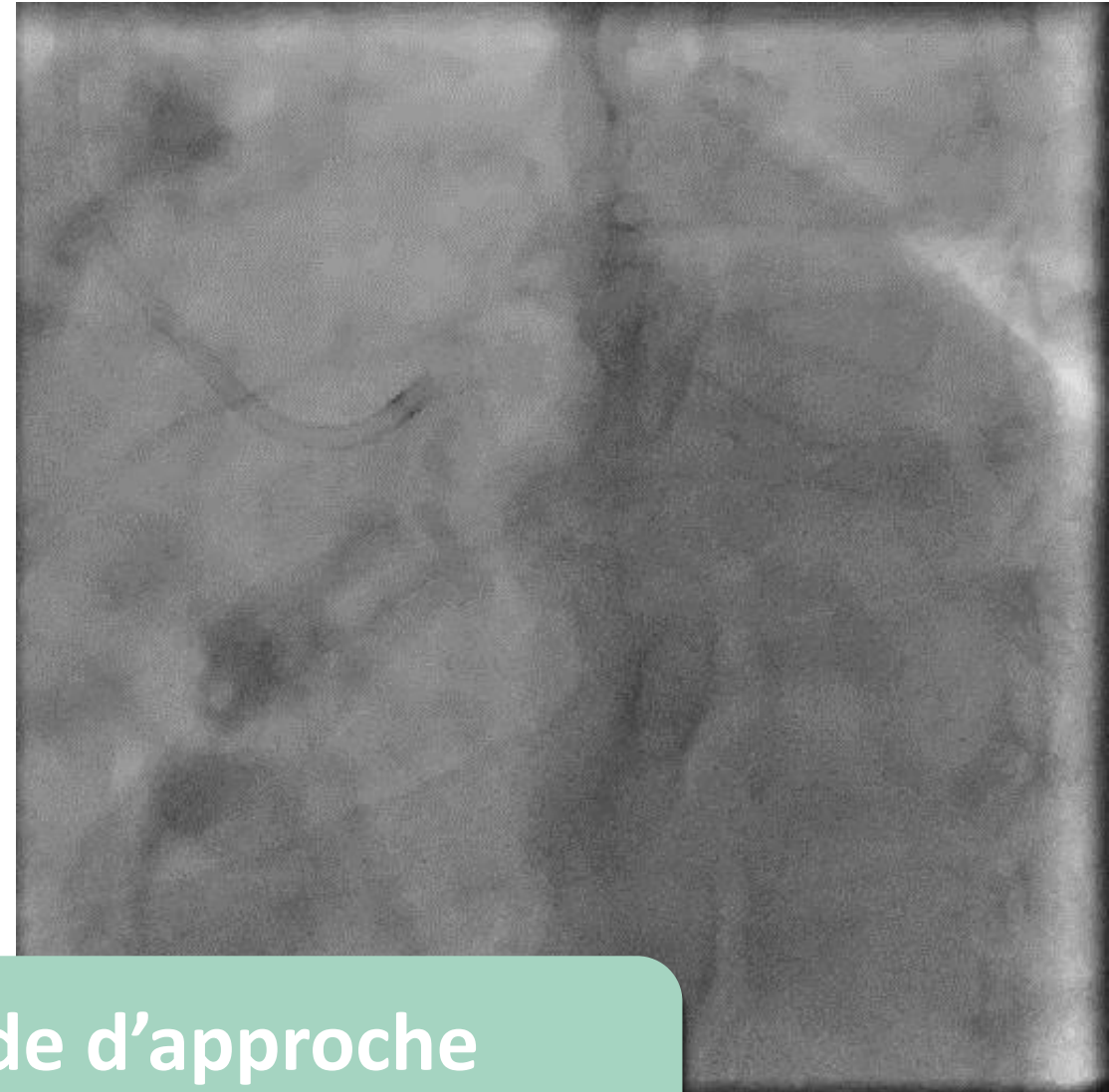
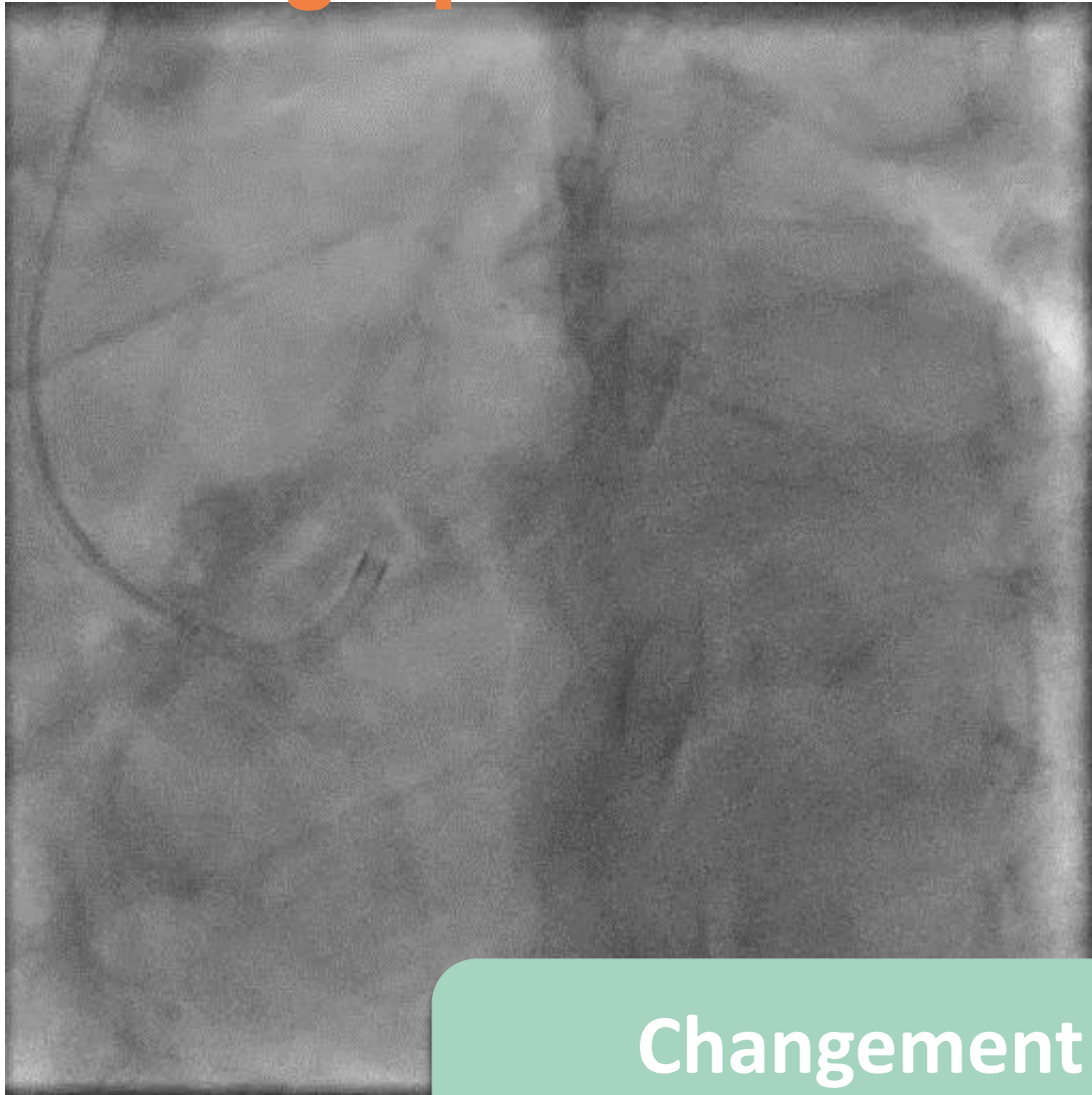


Angioplastie



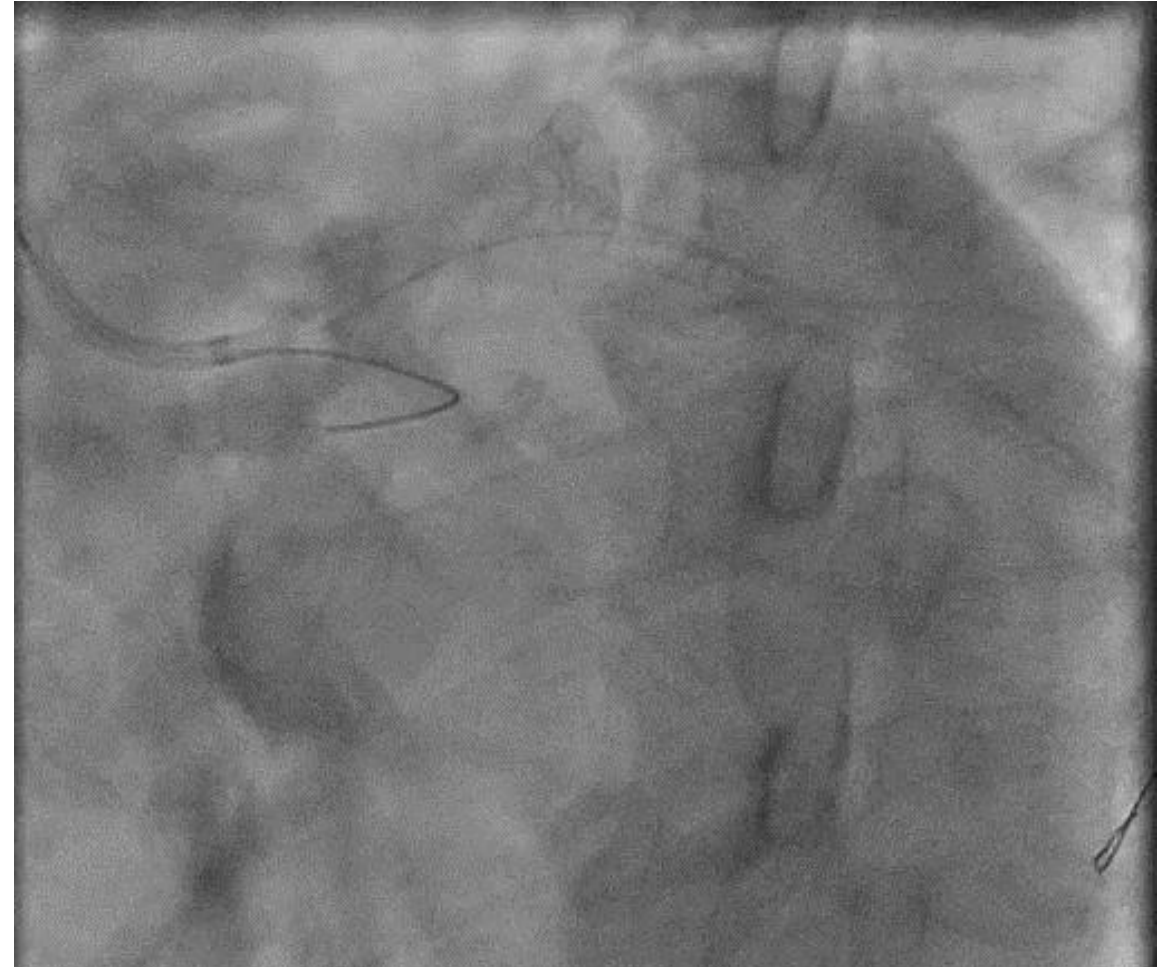
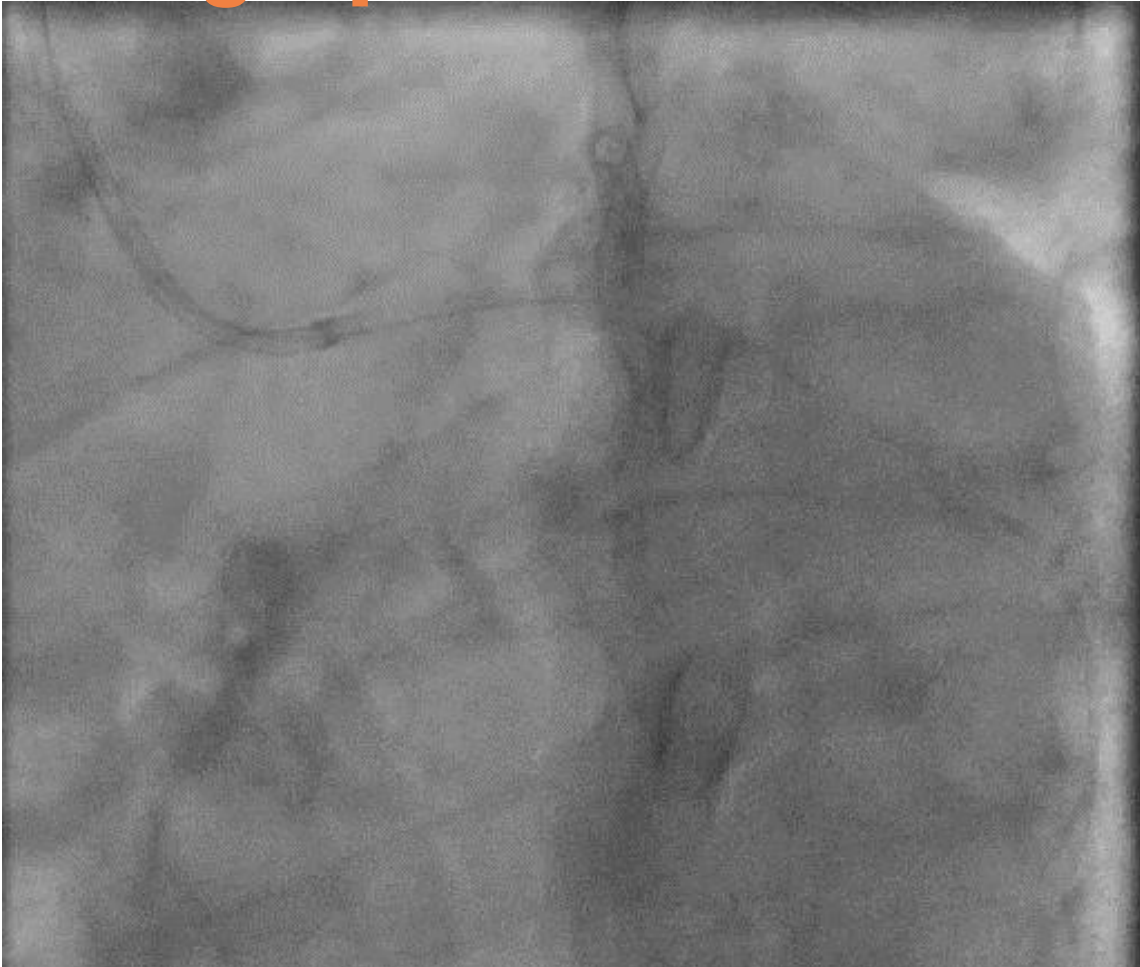Débordement du stent TC
Cathétérisme complexe

Angioplastie



Changement de sonde d'approche
pour une JL 3.5

Angioplastie

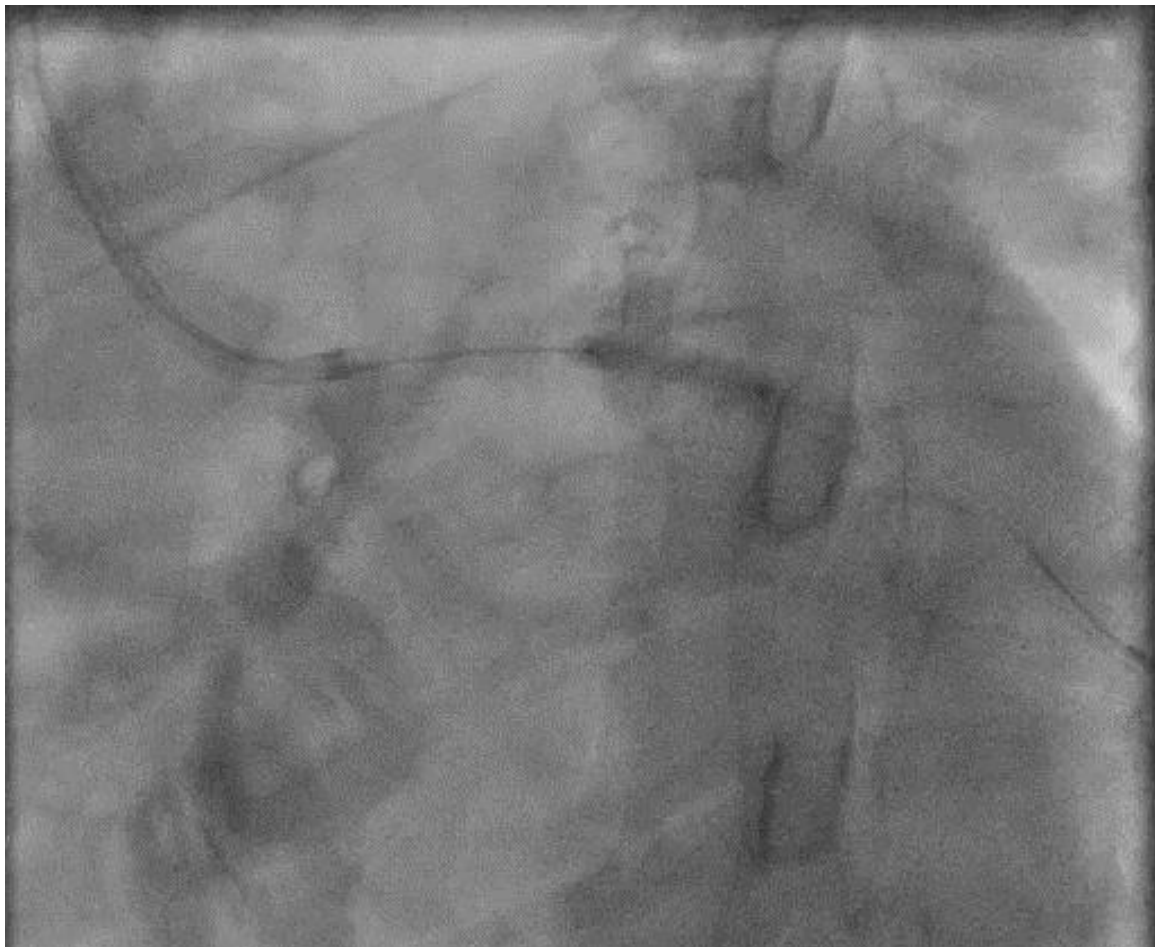


Whisper extra support

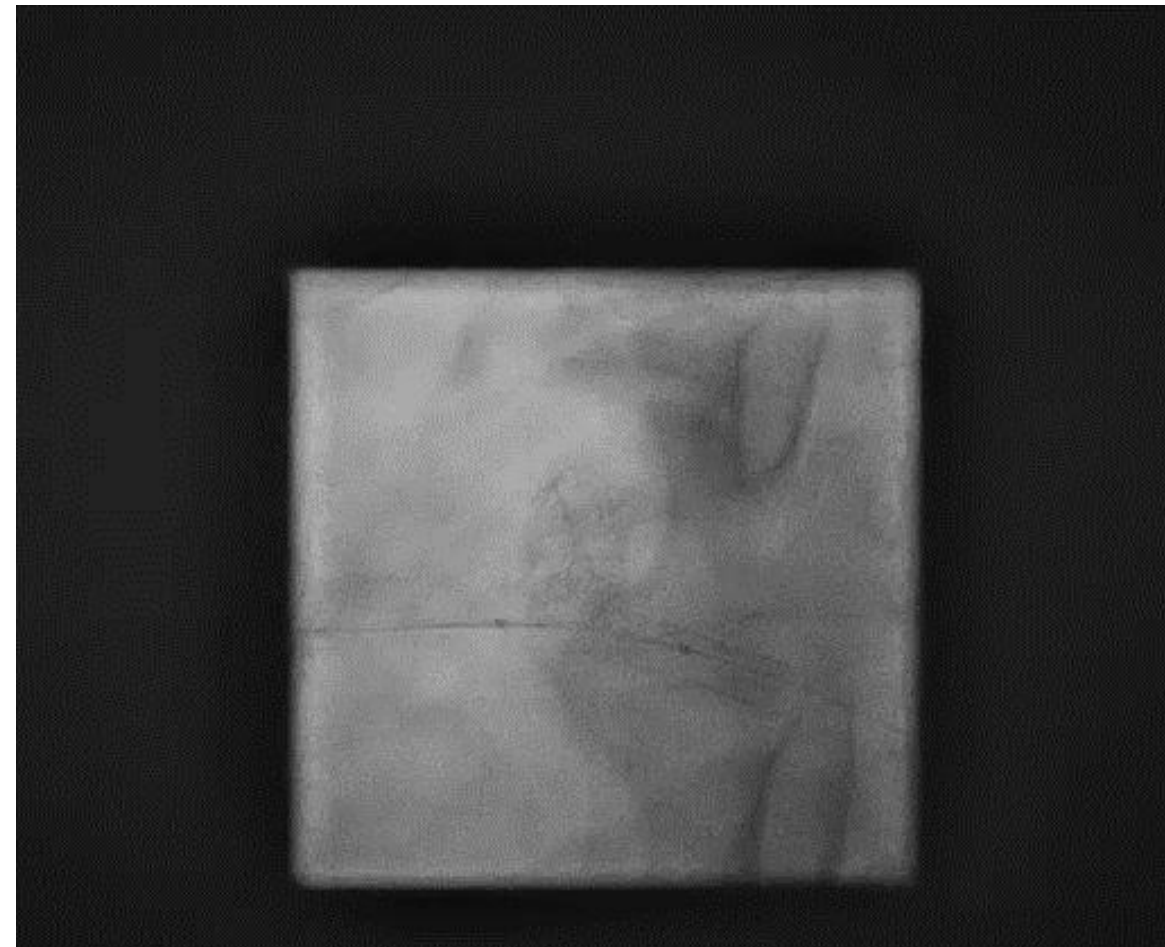
Push sur guide

Progression intraluminaire du Sion blue

Angioplastie

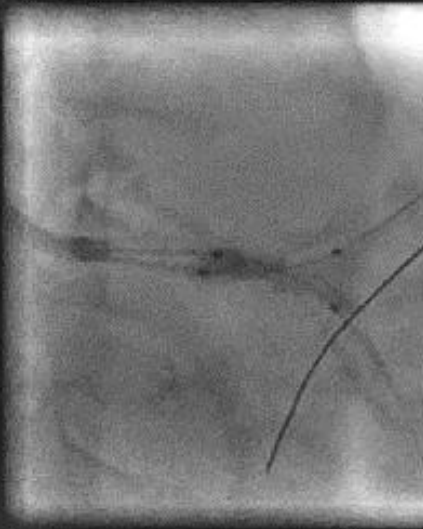

**BALLON NC PIPIT 3.0 X 15 MM
(SMT)**

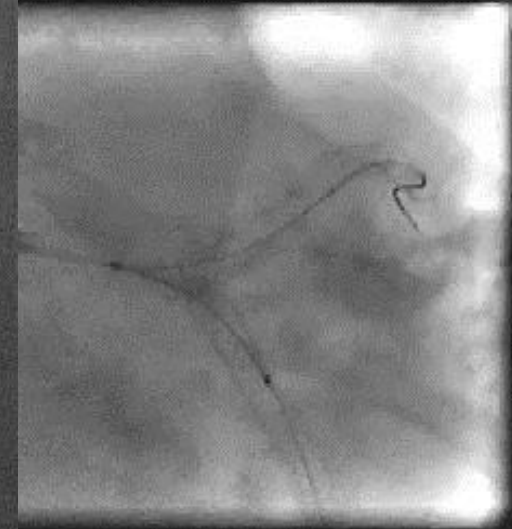
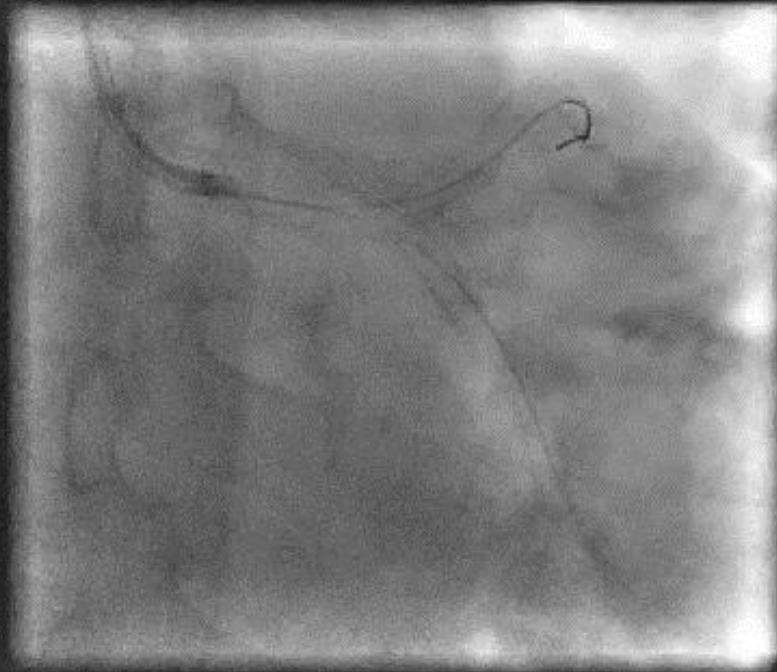


**Shockwave C2+ IVL Catheter
3.0 x 12mm**

Angioplastie



**Kissing
Sapphire II Pro 3,0
(Orbus)**




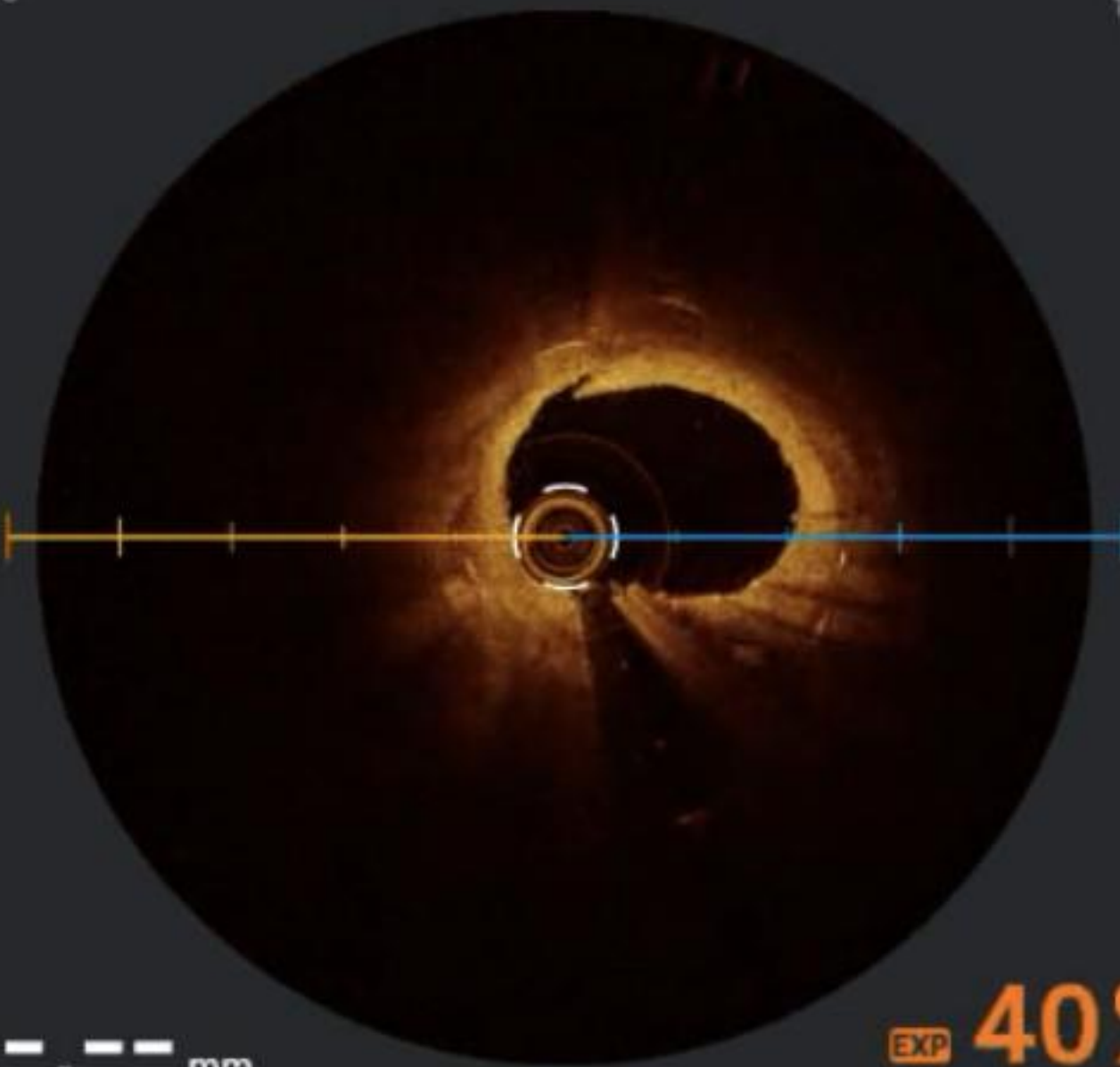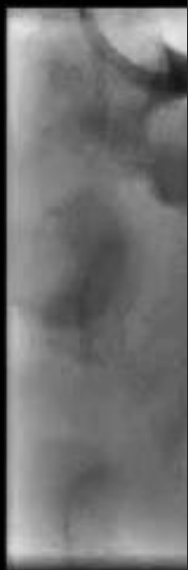
**PLEASE NEO 3.0 X 20
MM (Braun)**

OCT

F:170

1 mm

1 mm



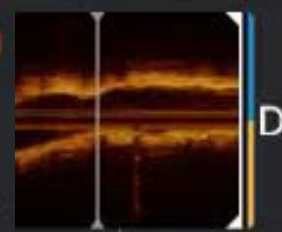
EXP --%

2,19 mm²

E -- mm
B 1,72 mm

EXP 40%

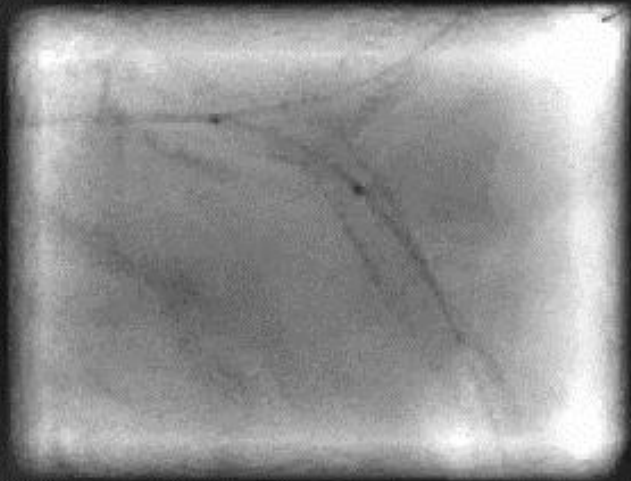
LA 4,23 mm²



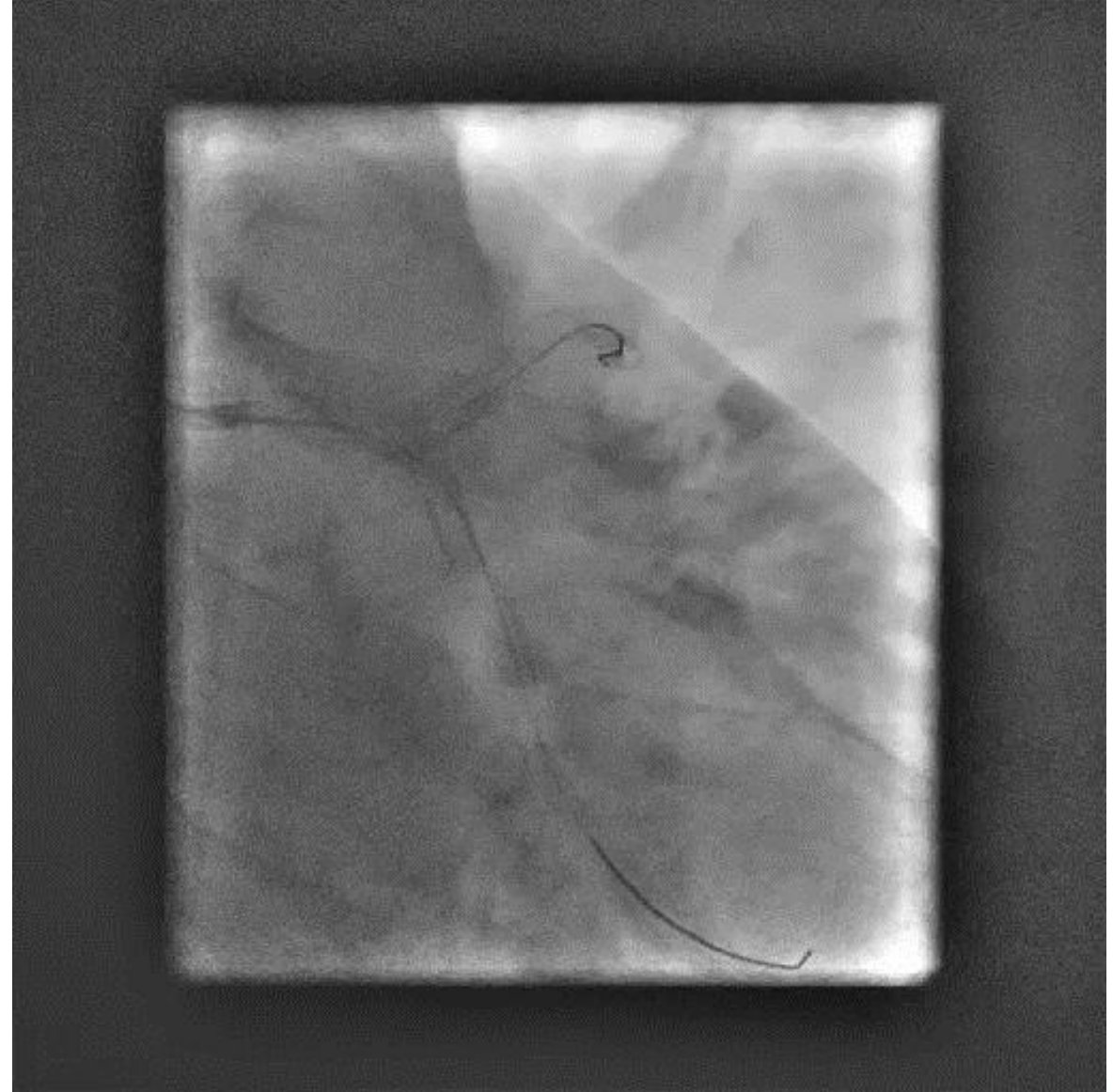E --, -- mm

B 2,30 mm

POT



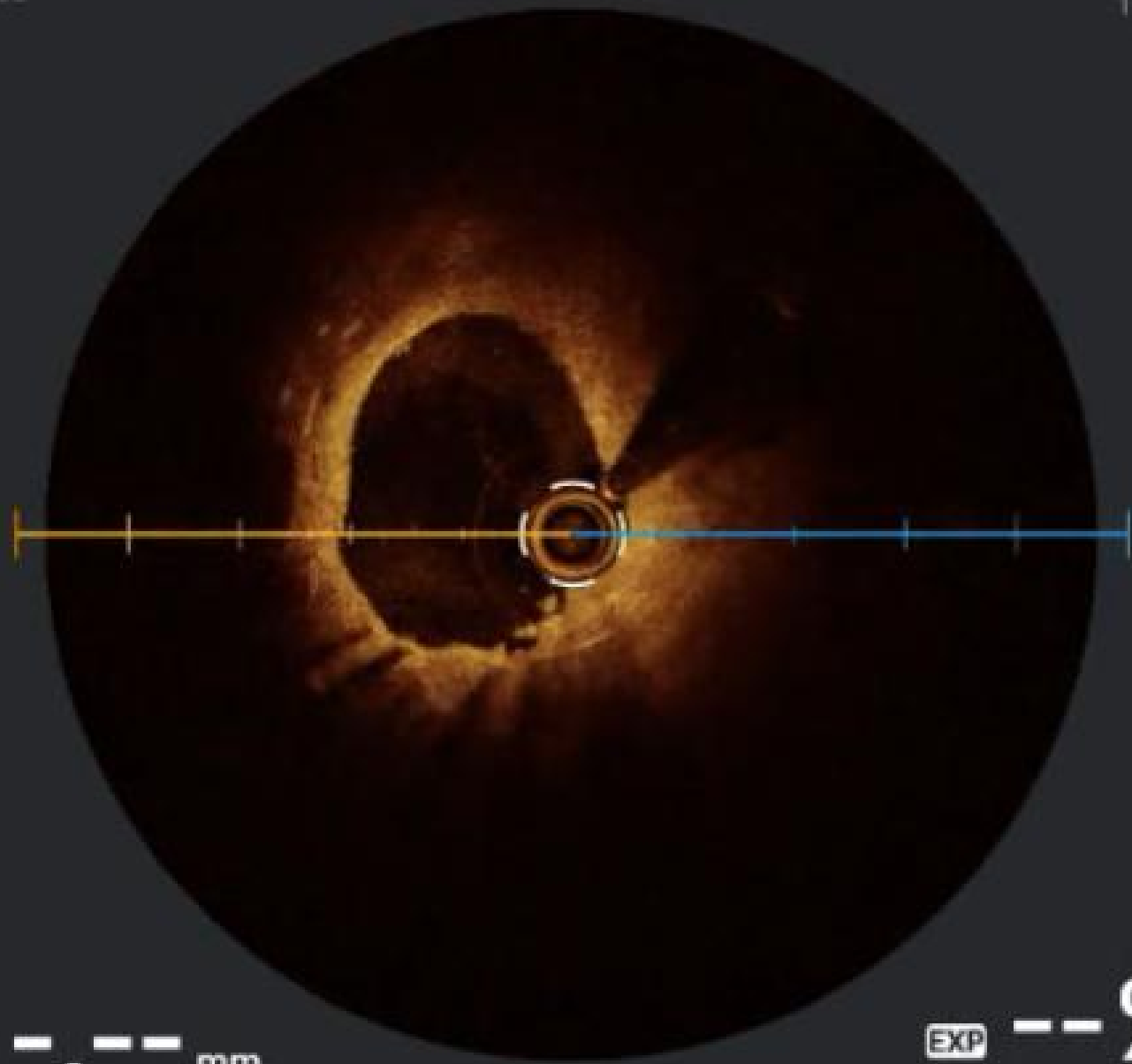
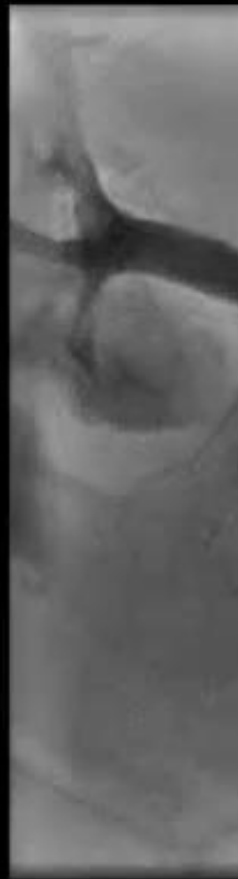**BALLON NC PIPIT
3.5 X 12 MM (SMT)**



F:189

1 mm

1 mm



EXP --%
2,06 mm²

E -- mm
L 1,67 mm

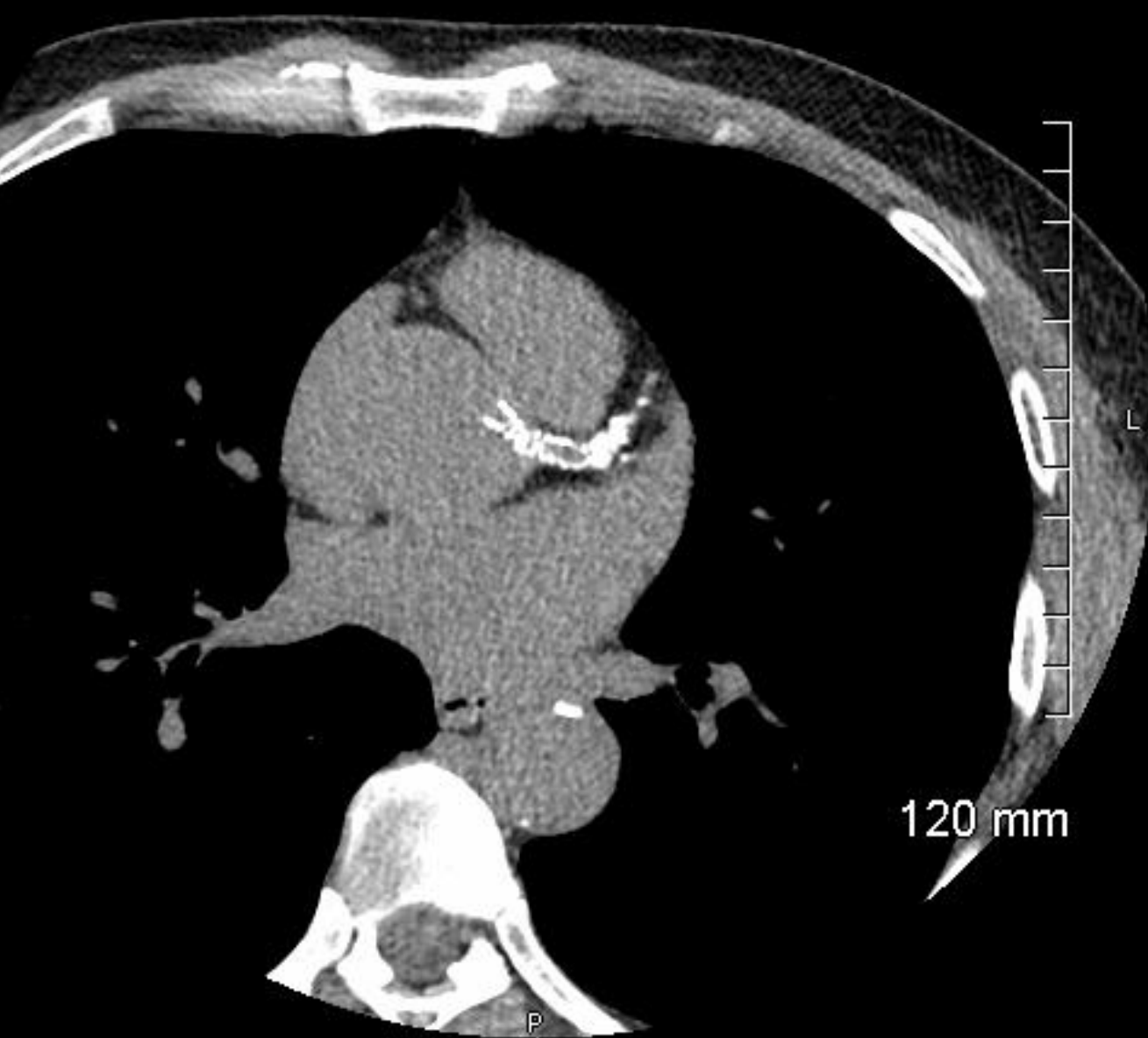


E --, -- mm
L 2,73 mm

EXP --%
LA 5,88 mm²

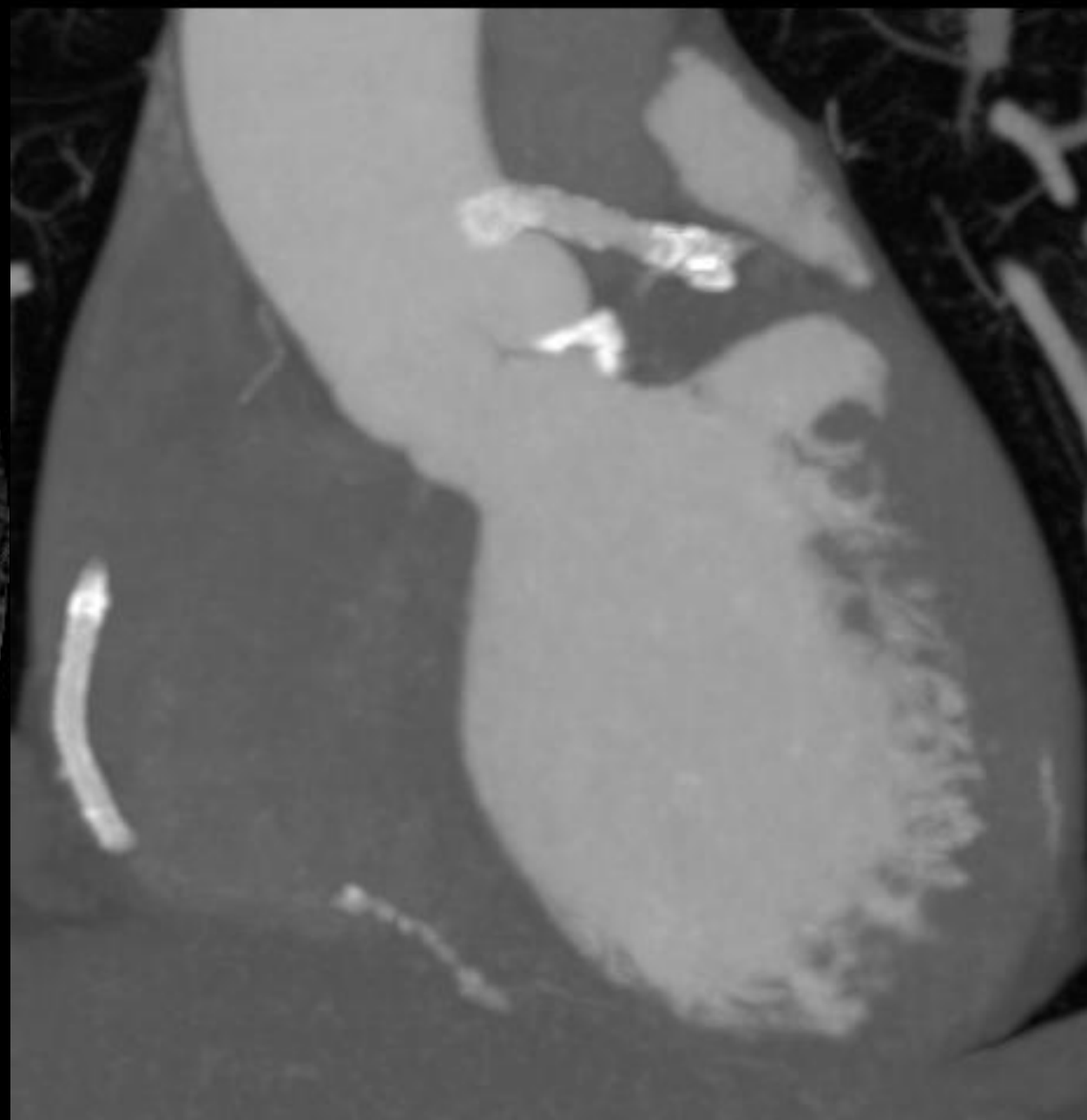
A

NOT FOR DIAGNOSIS

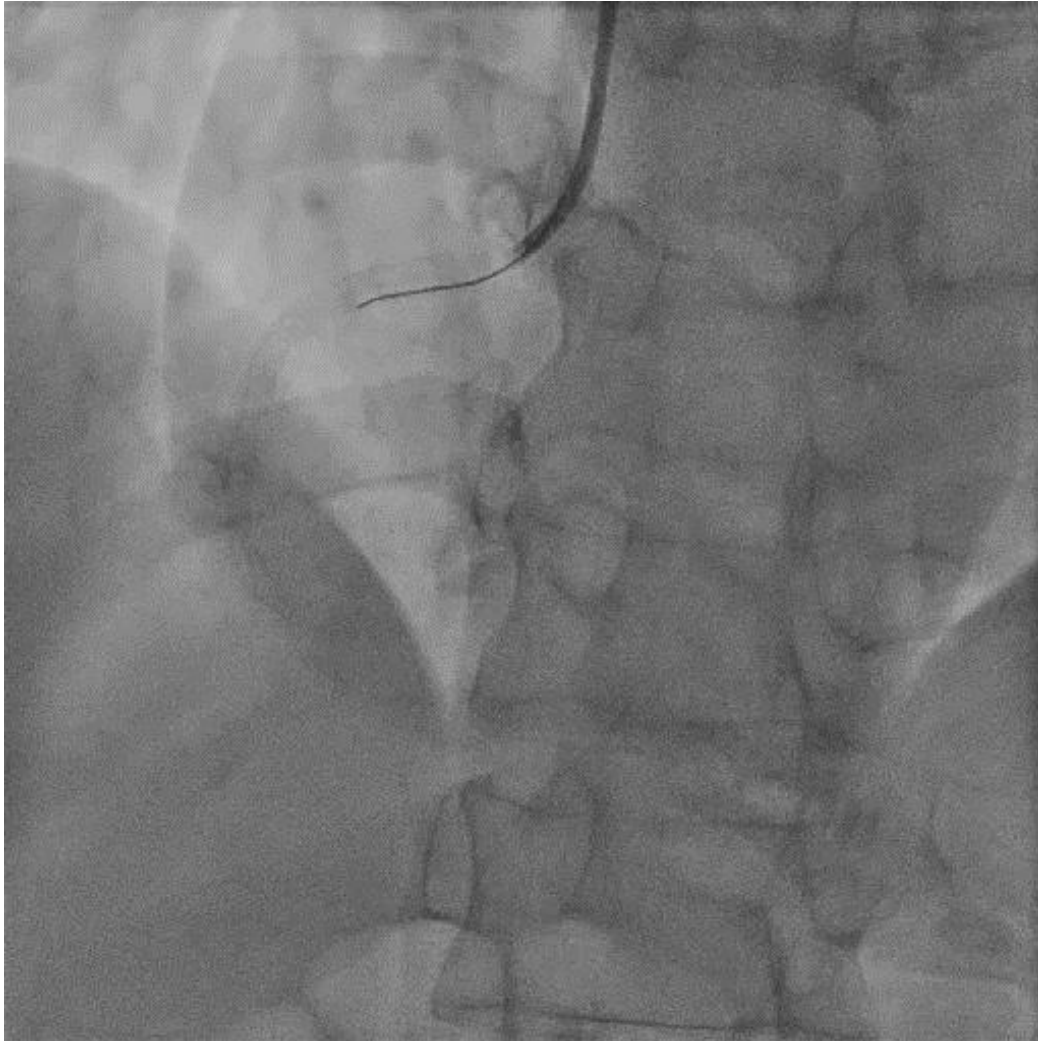


SAL

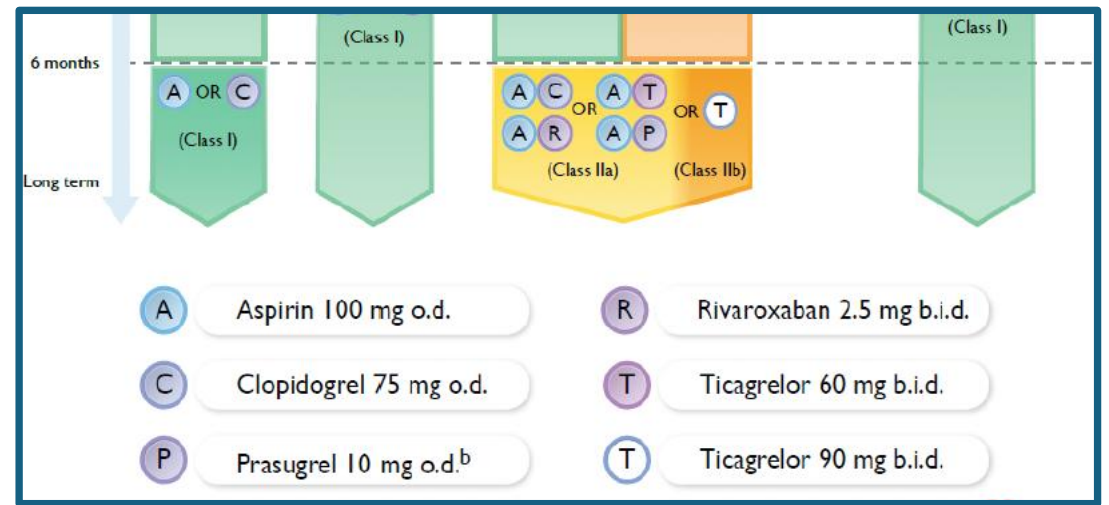
NOT



Evolution



- Asymptomatique à 6 mois
- Echographie d'effort négative
- Durée AAP un an



Take Home Message

- Stenting du TC ostial = réel challenge
- Débordement dans l'aorte à éviter +++
- Guidage par imagerie endocoronaire
- Intérêt du Coroscanner



28-30
JANVIER
2026

MARSEILLE
PALAIS DU PHARO

Une histoire de mailles

Simon BERGER, Docteur Junior
CHU Clermont-Ferrand
sberger1@chu-clermontferrand.fr



CARDIOLOGIE
• CHU •
CLERMONT
FERRAND