



28-30
JANVIER
2026

MARSEILLE
PALAIS DU PHARO

Redo TAVI: les aspects techniques

Didier TCHETCHE



CONFLITS D'INTÉRÊTS

Consultant : *Abbott, Boston Scientific, Caranx Medical, Edwards LifeSciences, Medtronic, Meril, Pi-Cardia, T-Heart.*

Minor Shares : *Carvolix, Electroducer, T-Heart,*

Enseignements de pratique clinique

Procédure de plus en plus fréquente

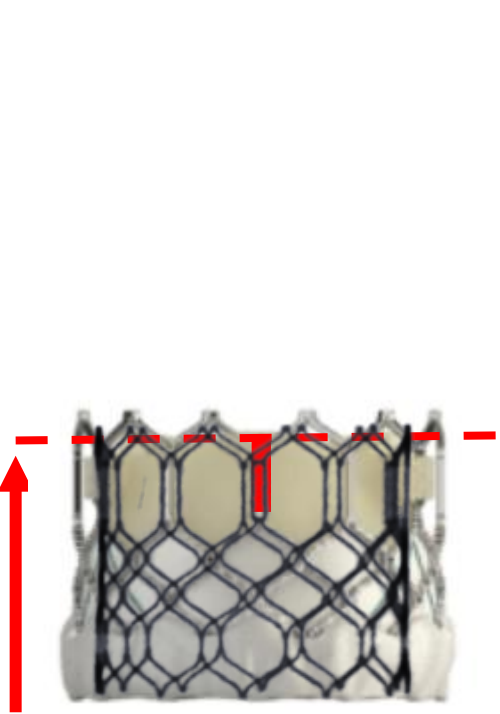
Importance de la procédure TAVI initiale

Sous-expansion systématique des prothèses TAVI

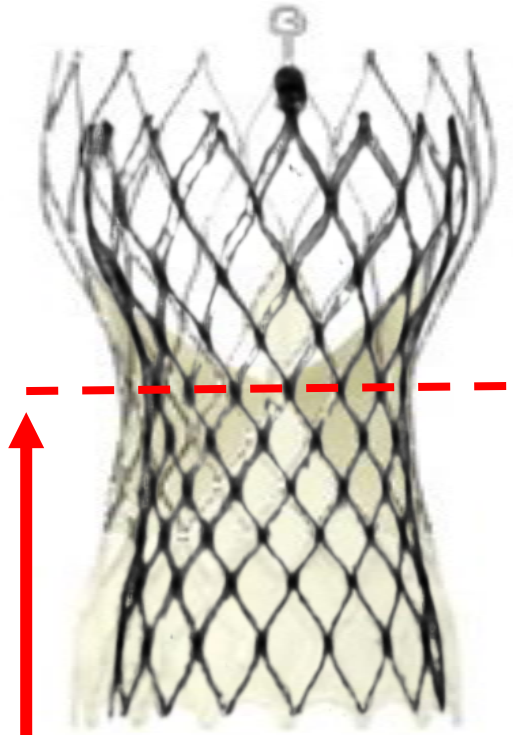
Différence entre dégénérescence sténosante et fuyante

Risque élevé d'obstruction coronaire et séquestration de sinus

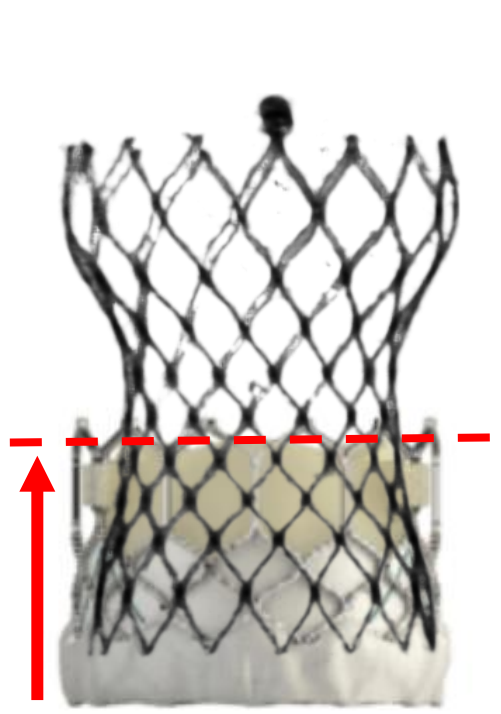
Variabilité du plan de la Neo Skirt



Short in Short

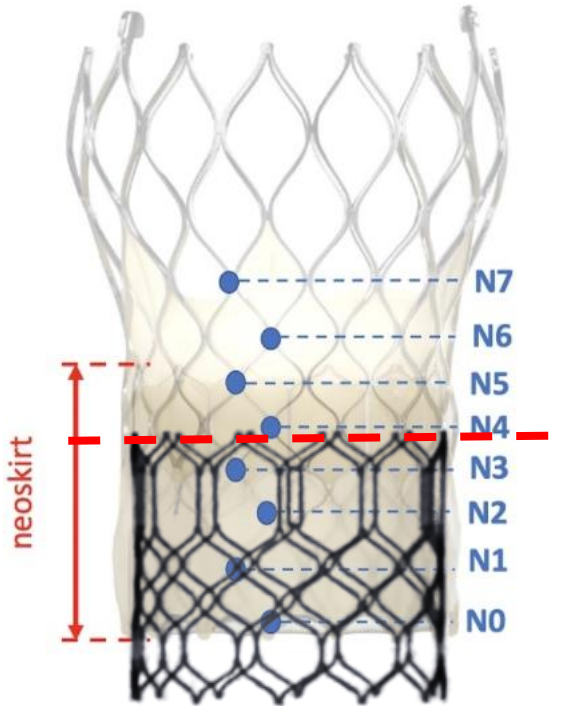


Tall in Tall



Tall in Short

NSP unique



Short in Tall

NSP multiple

➤ 2020: TAVI with SAPIEN 3 (native annulus 21.5 mm)**2025**

- **Aortic EOA 1.55 cm²**
- **Mean gradient 13 mmHg**
- **Peak Velocity 1.9 m/sec**
- **No AR**
- **LVEF 73%**
- **sPAP 25 mmHg**



- **Aortic EOA 0.77 cm²**
- **Mean gradient 42 mmHg**
- **Peak Velocity 4 m/sec**
- **AR central + moderate**
- **LVEF 60%**
- **sPAP 32 mmHg**

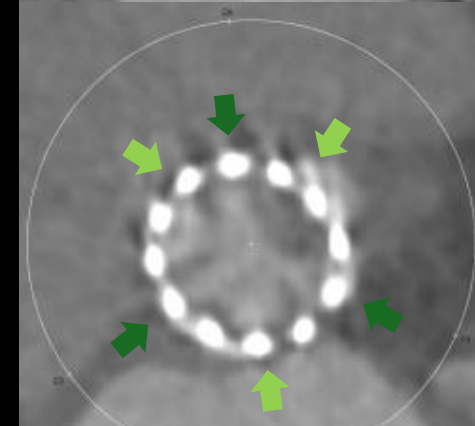
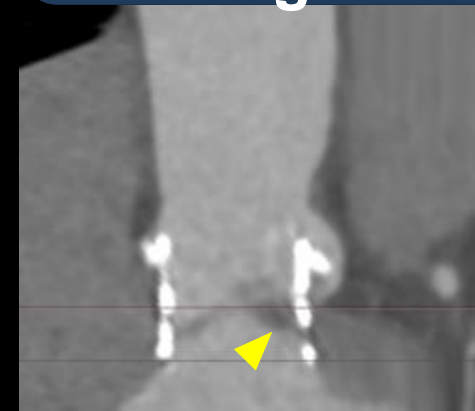
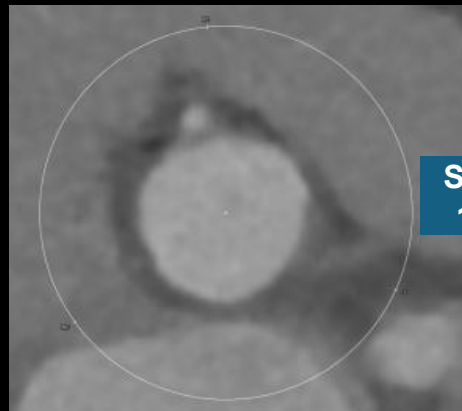
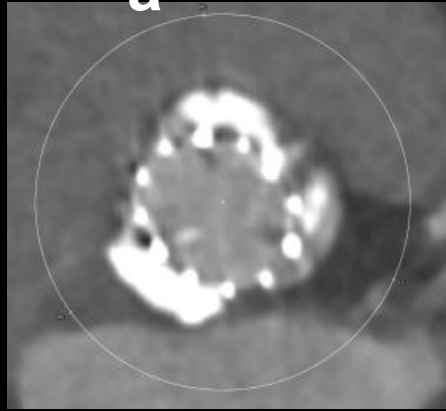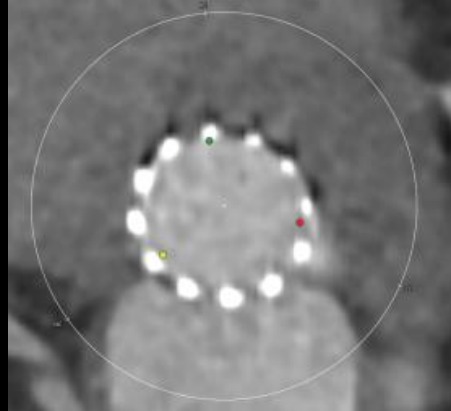
ID at bottom

Valsalva

STJ

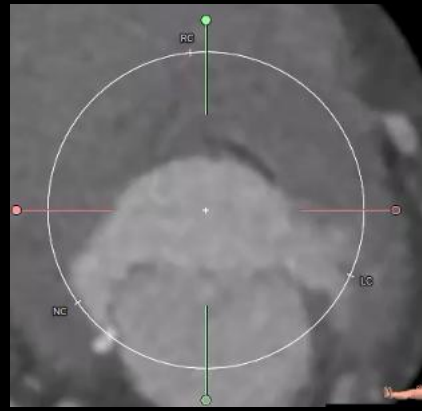
HALT

Commissural misalignment

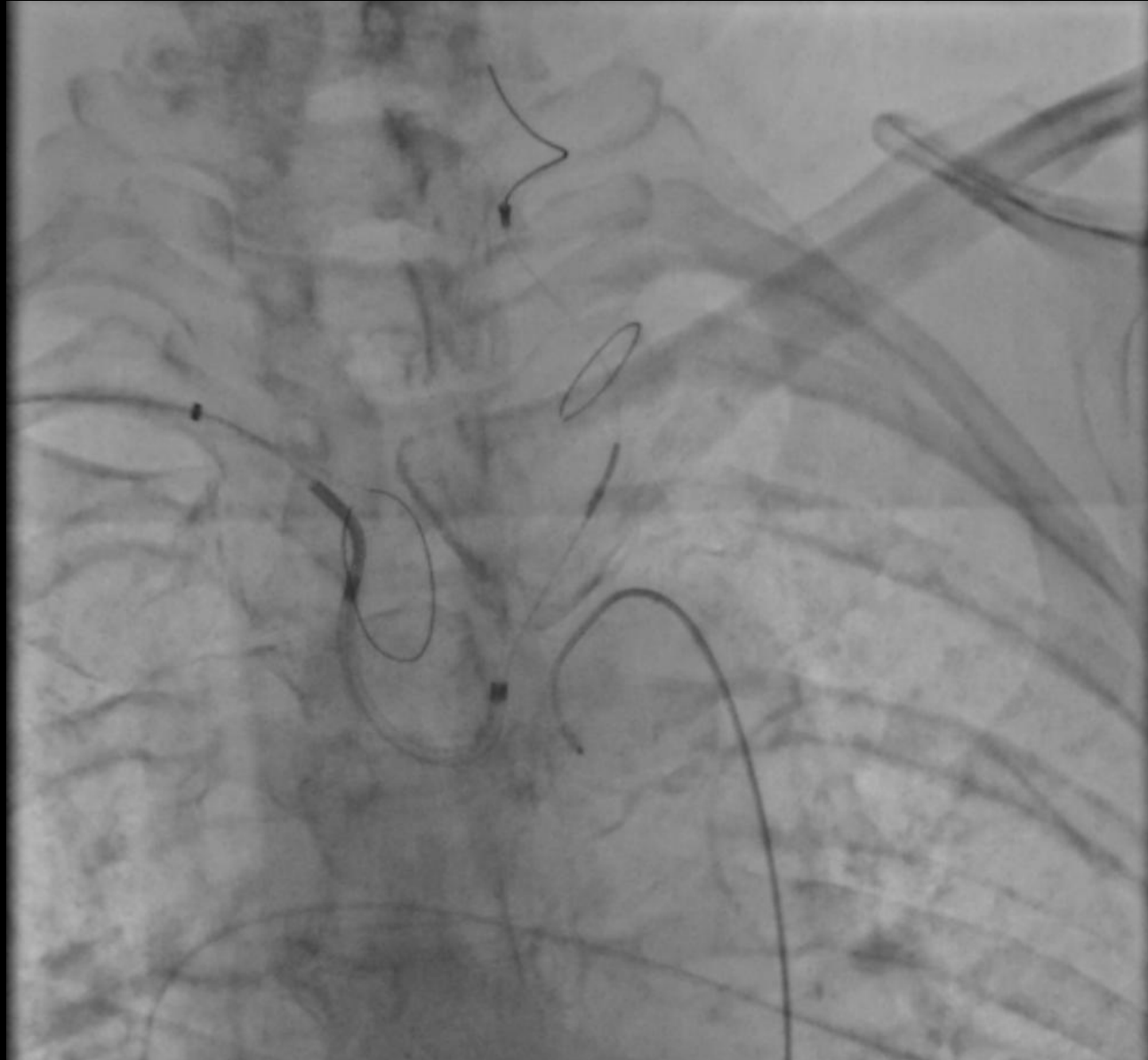


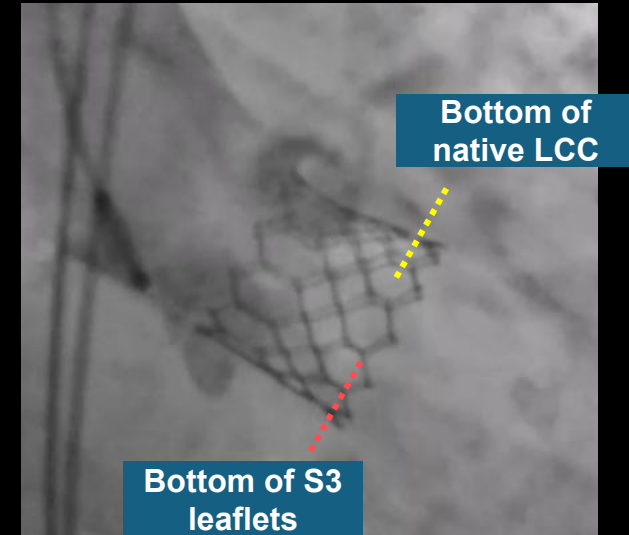
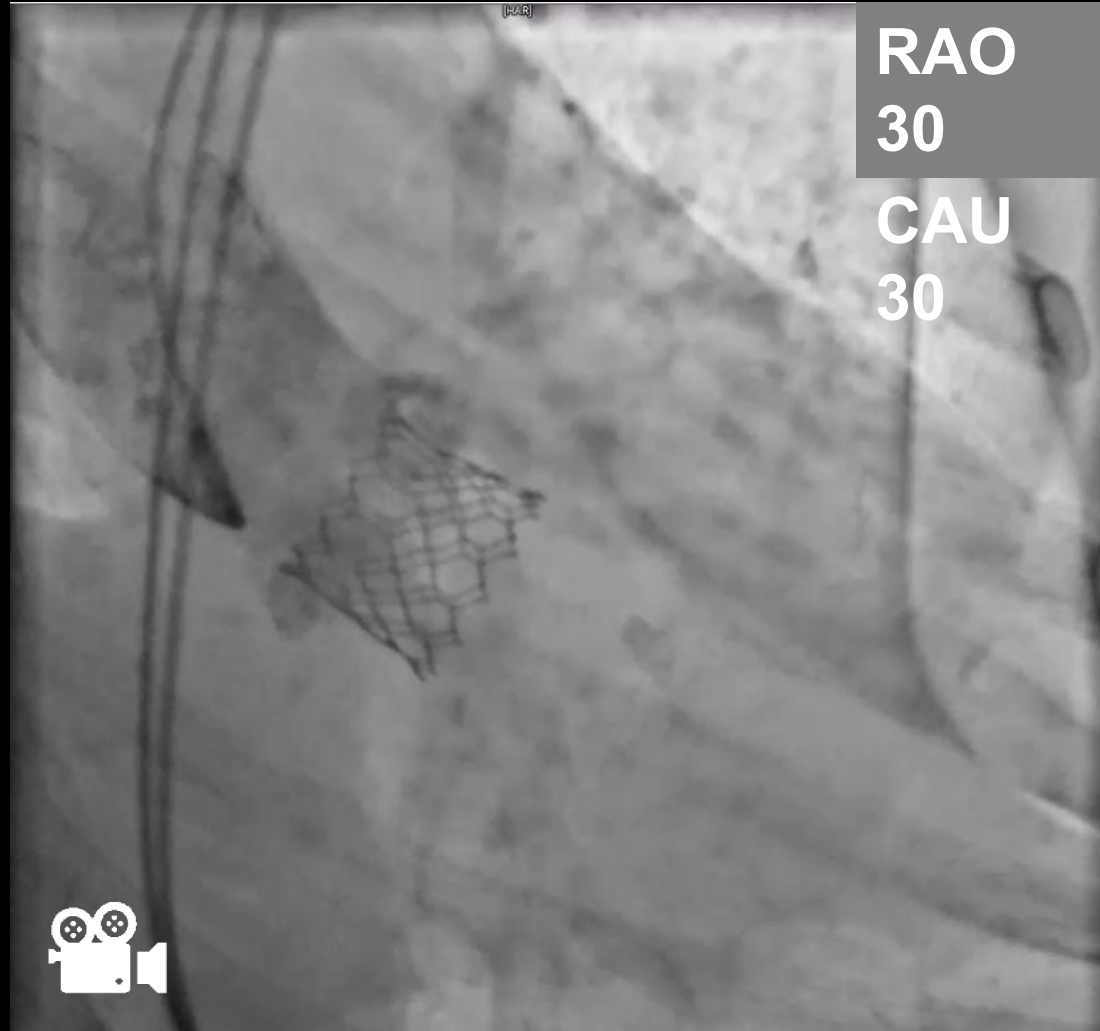
S3 commissure
Native commissure

Movie

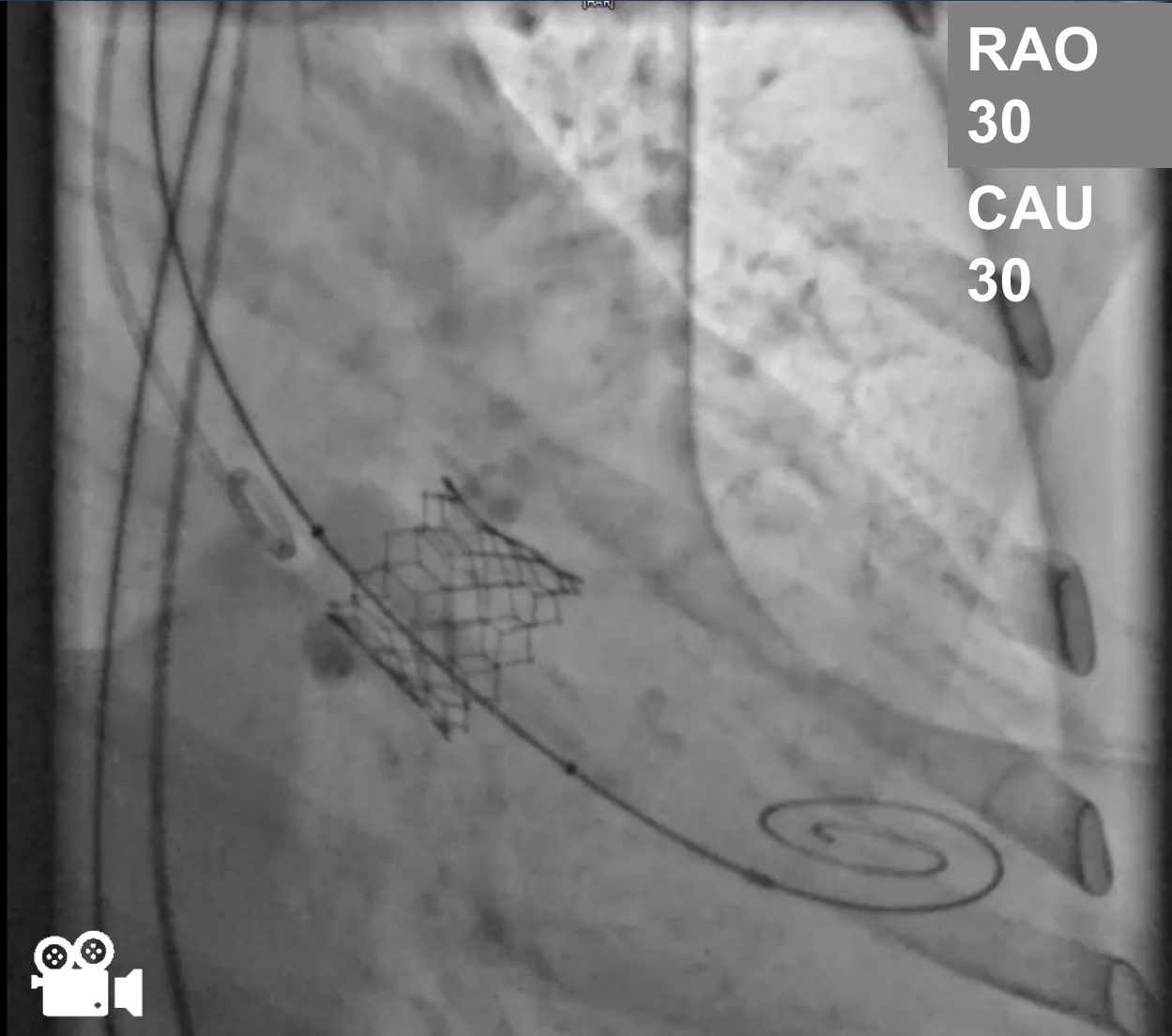


ID area	314.5 mm ²	SOV	30.9 mm
diameter	19.5*20.5mm	Valve height	19.1 mm
perimeter	63.0 mm	STJ	22.4 mm
peri-derived diameter	20.1 mm	STJ height	24.1 mm







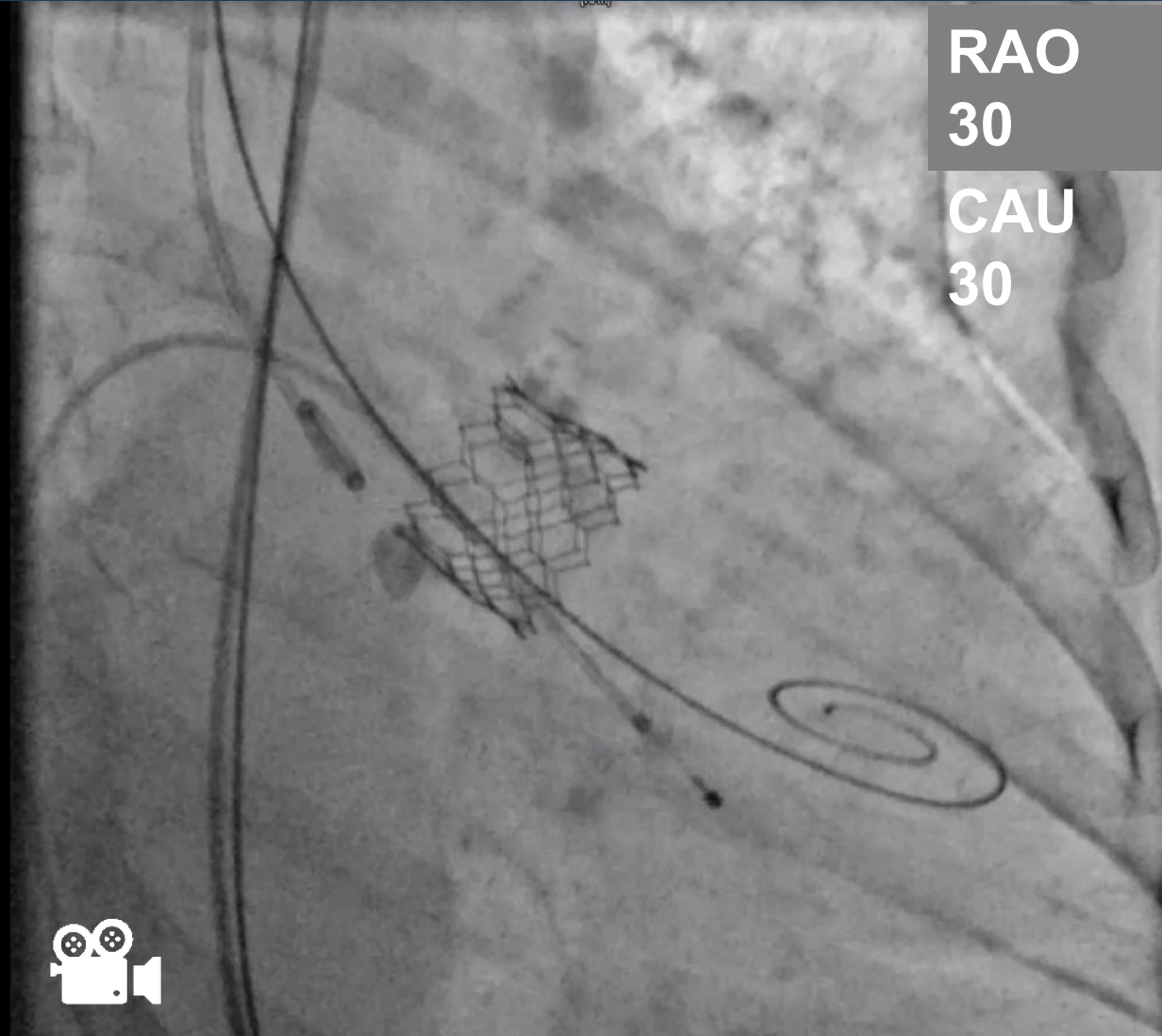
Bottom half of SOV was almost completely filled with thrombus and calcification
Bottom of native LCC and S3 leaflets were faintly visible to confirm the depth

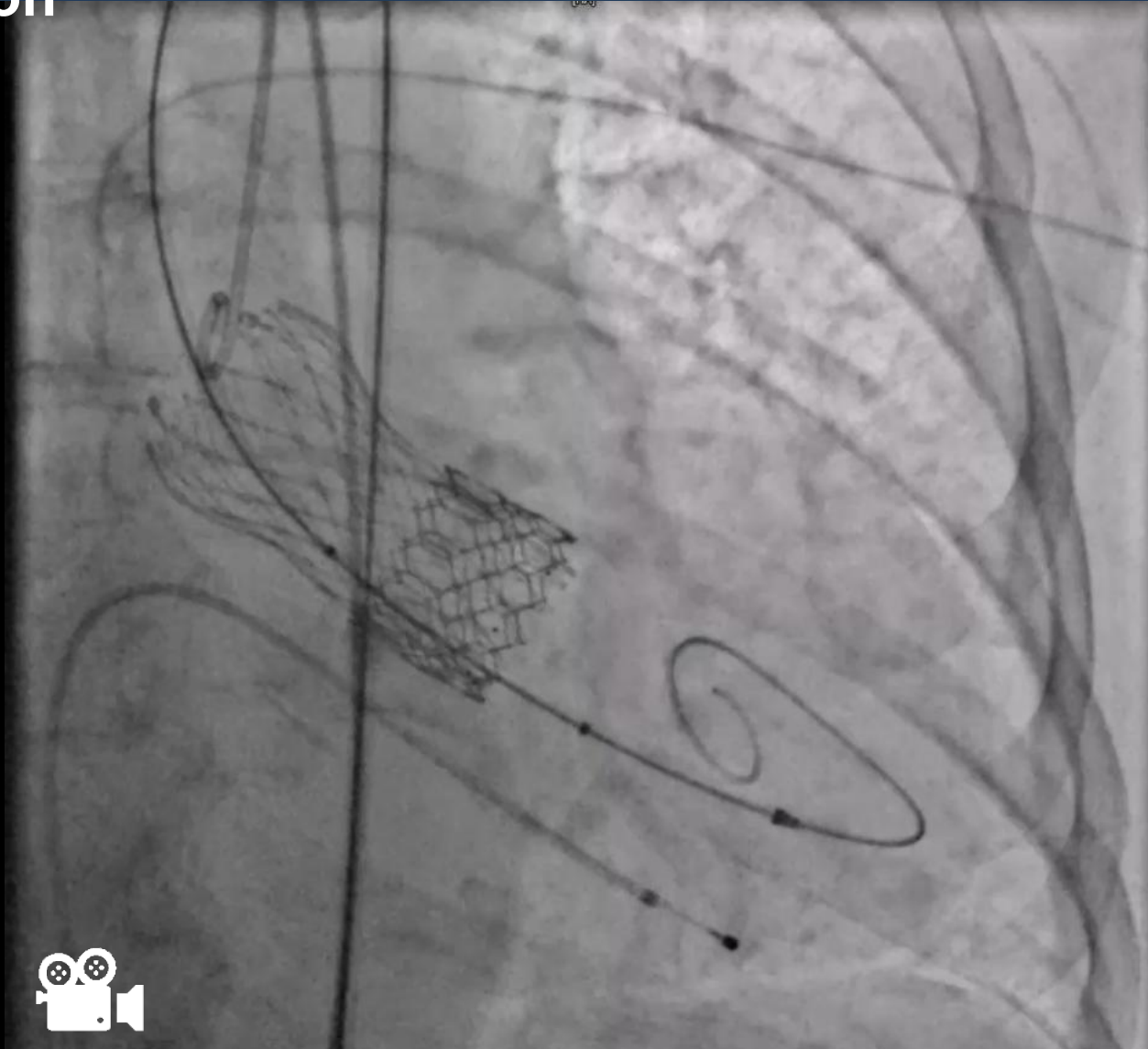


RAO
30

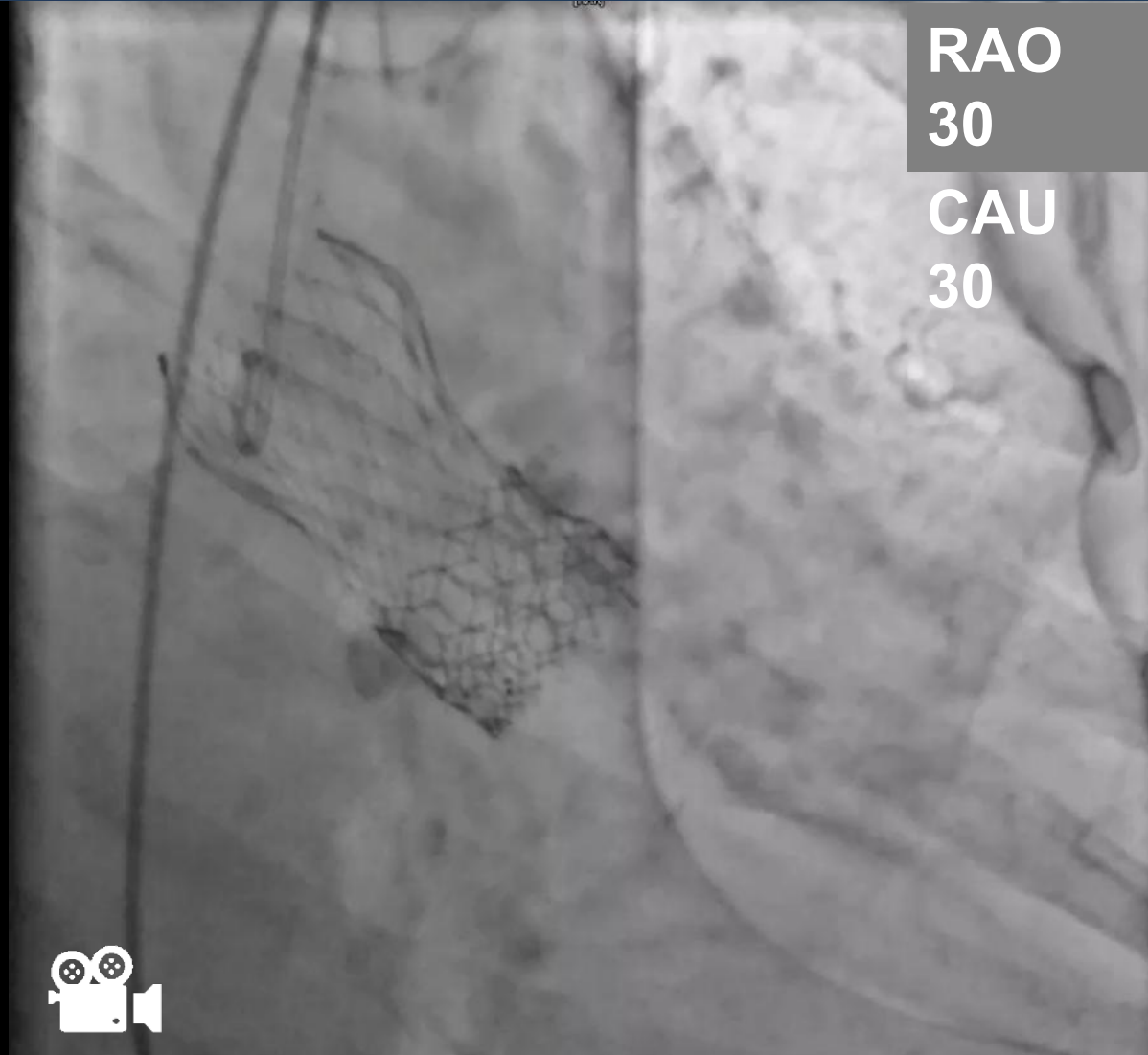
CAU
30



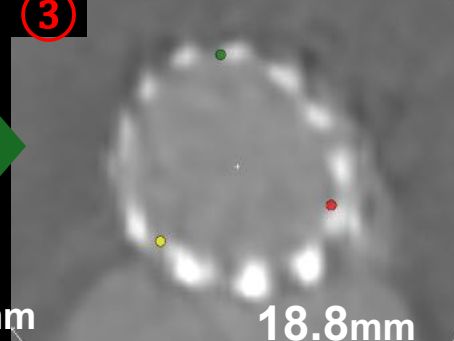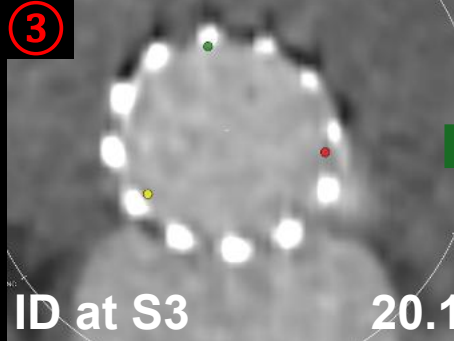
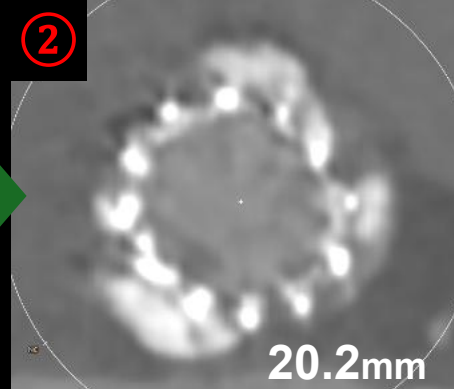
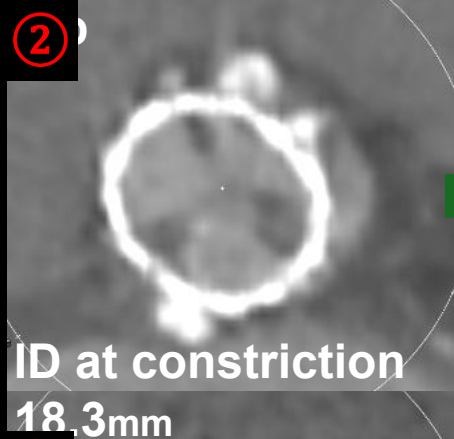
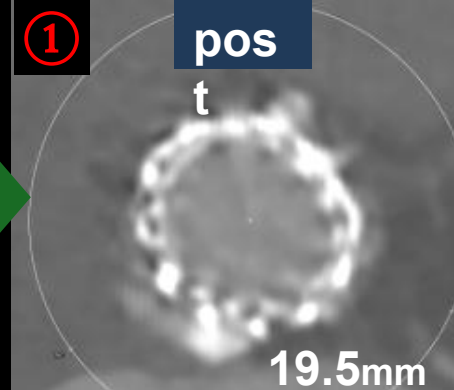
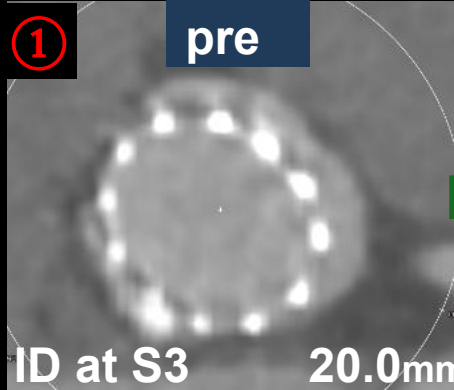
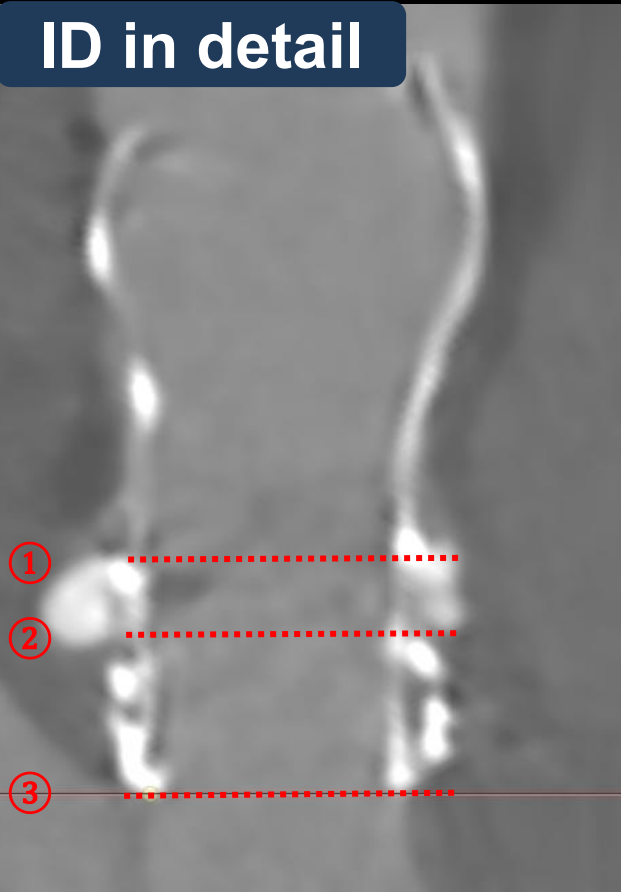




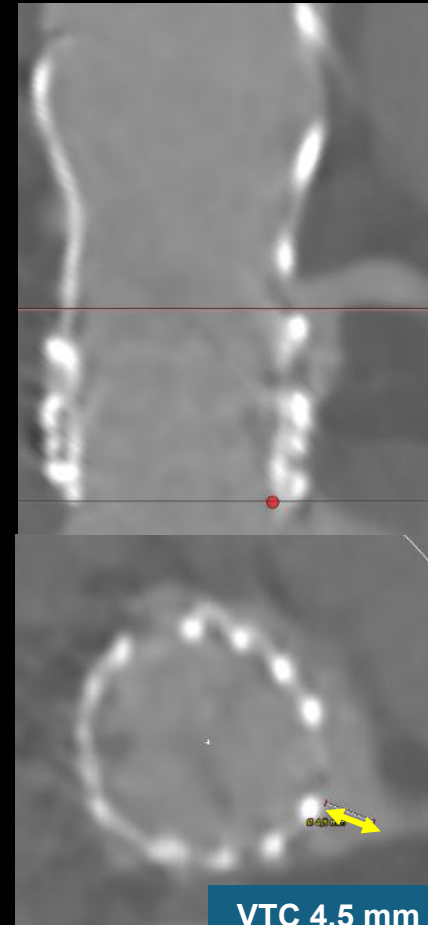
Post dilation with VACS 22 mm



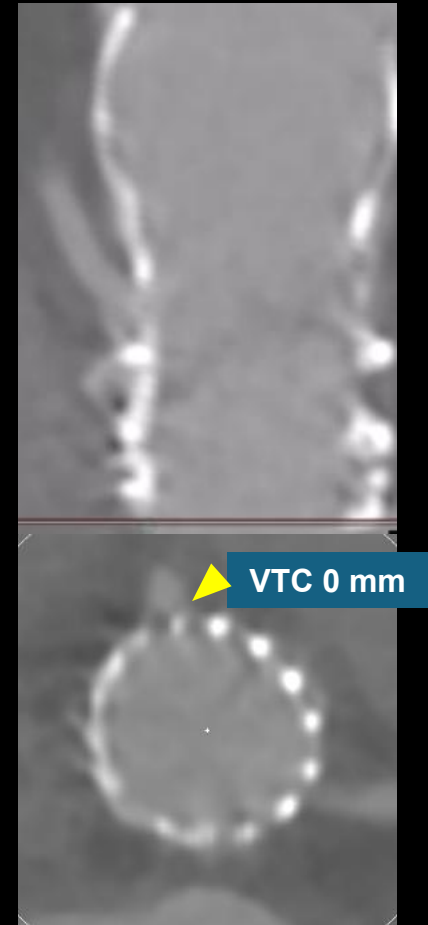
ID in detail



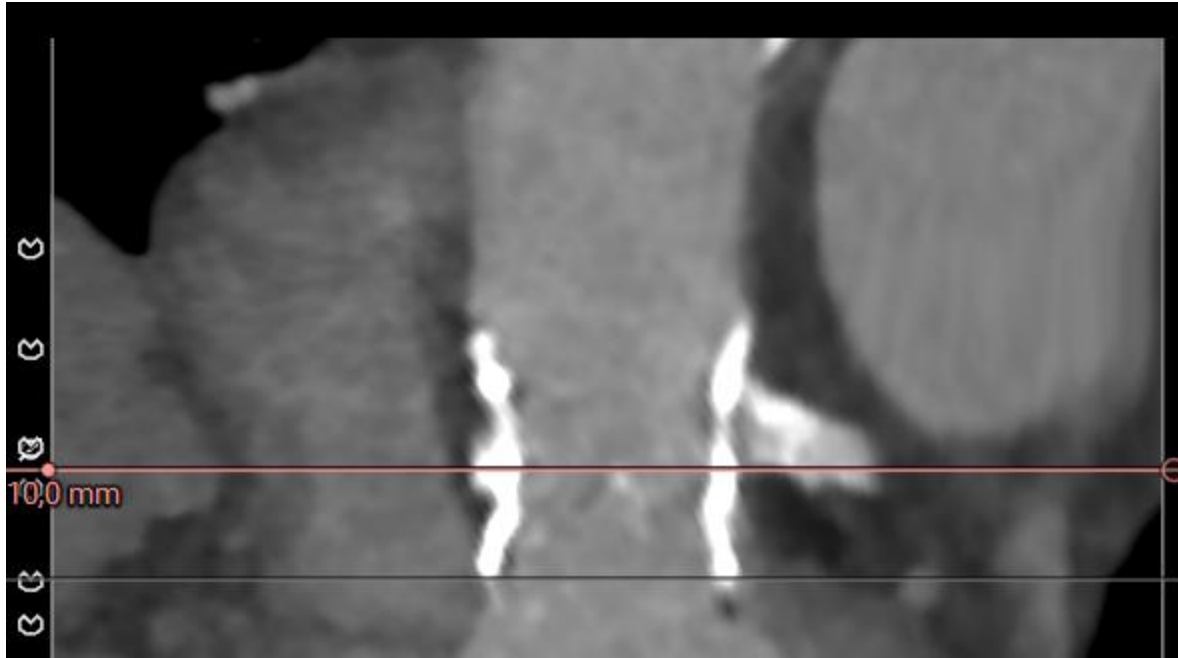LCA



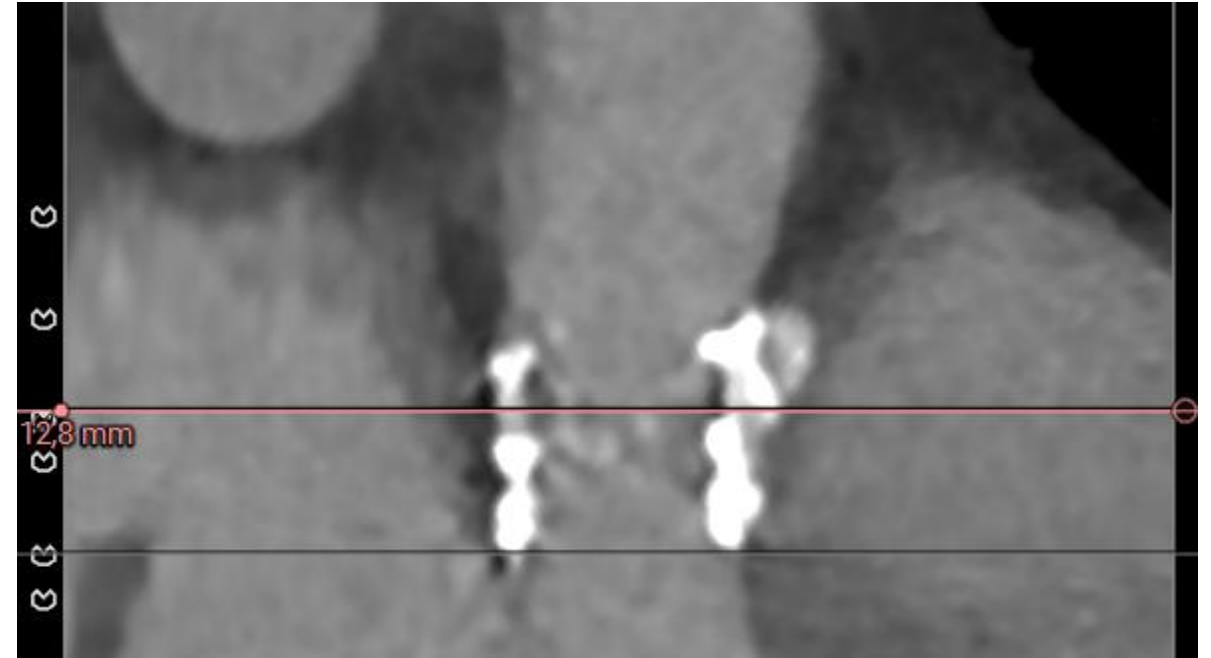
RCA



Risque d'obstruction coronaire élevé

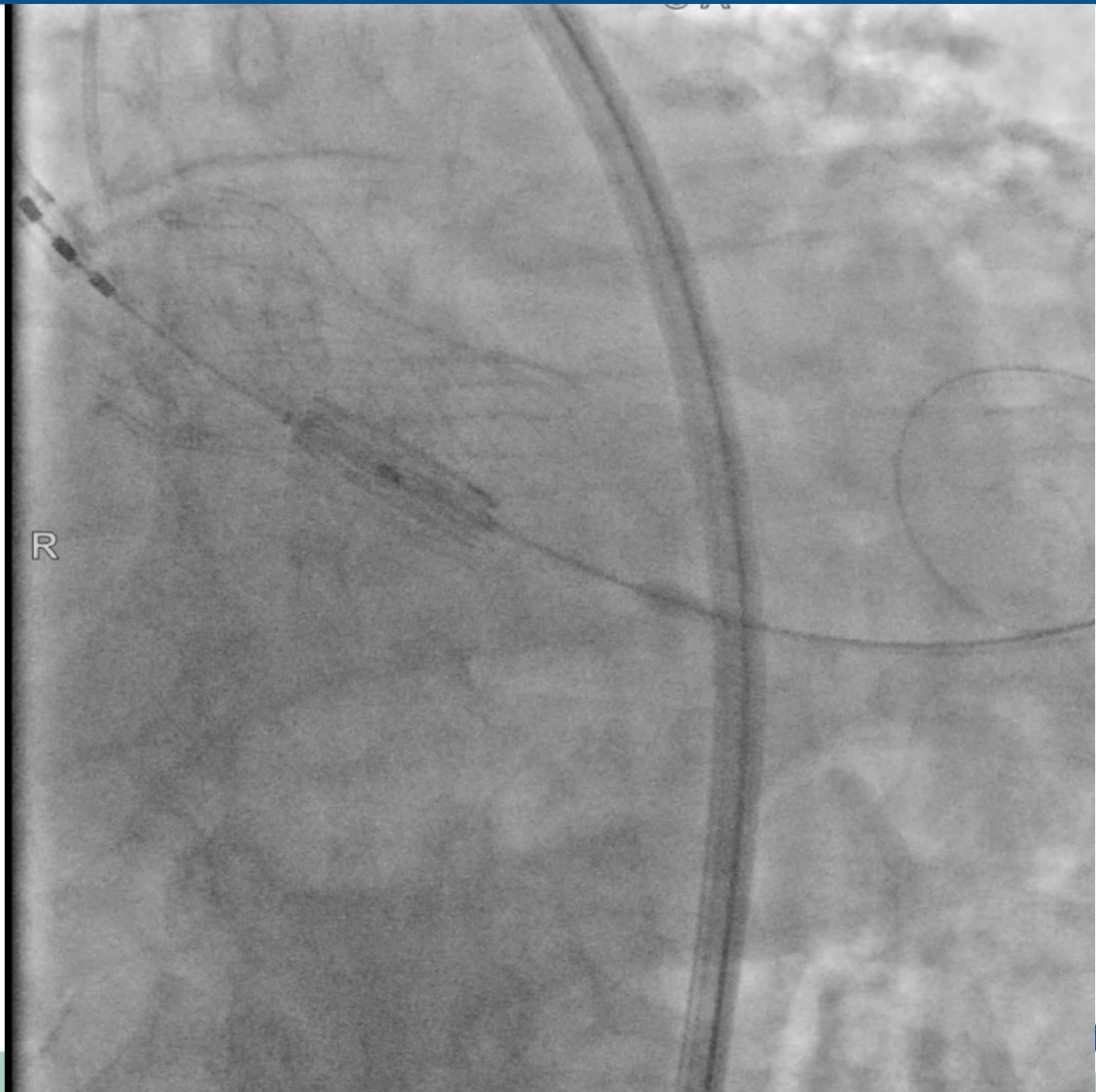

VTC Left main: 1 mm

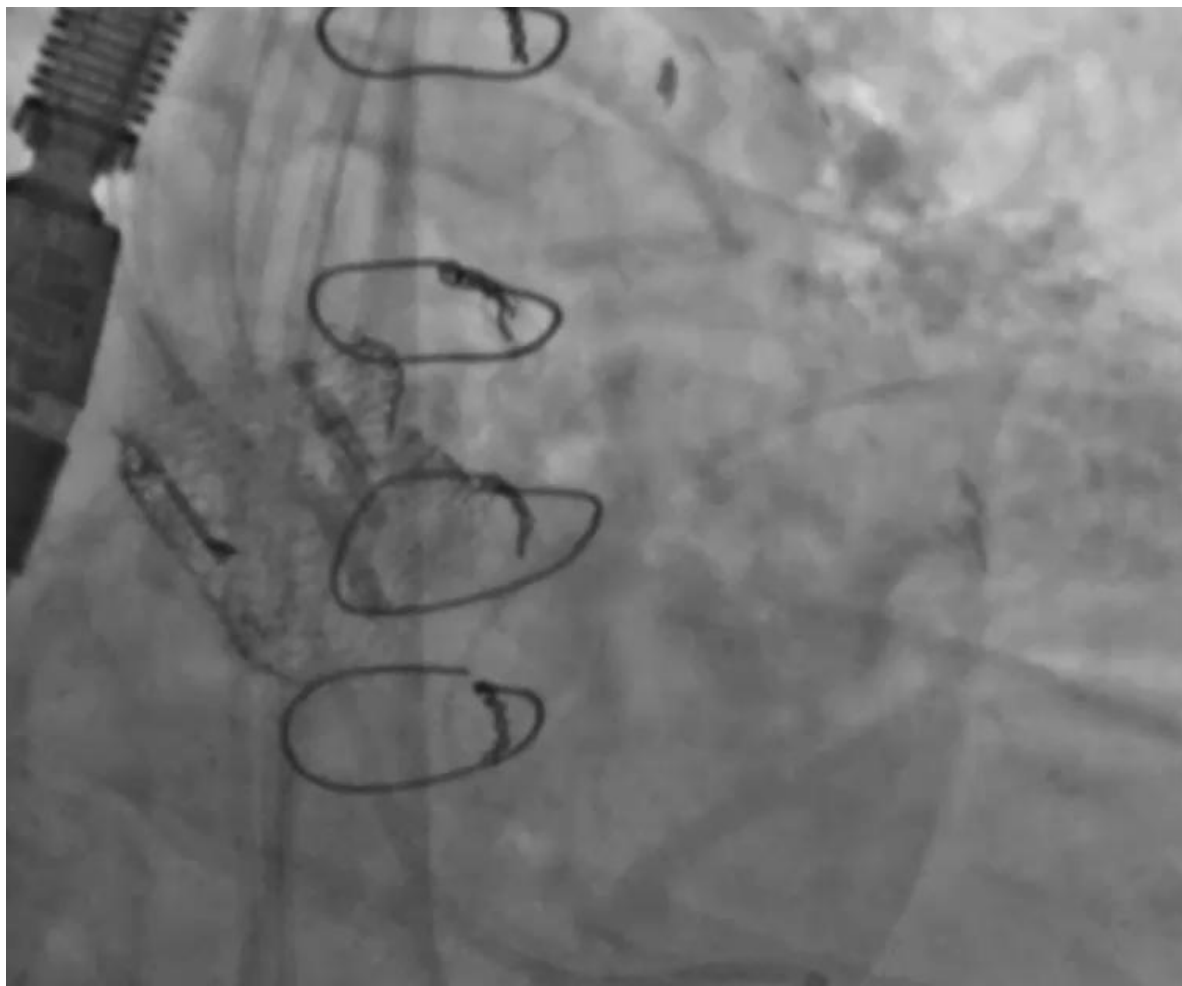


VTC RCA: 2 mm

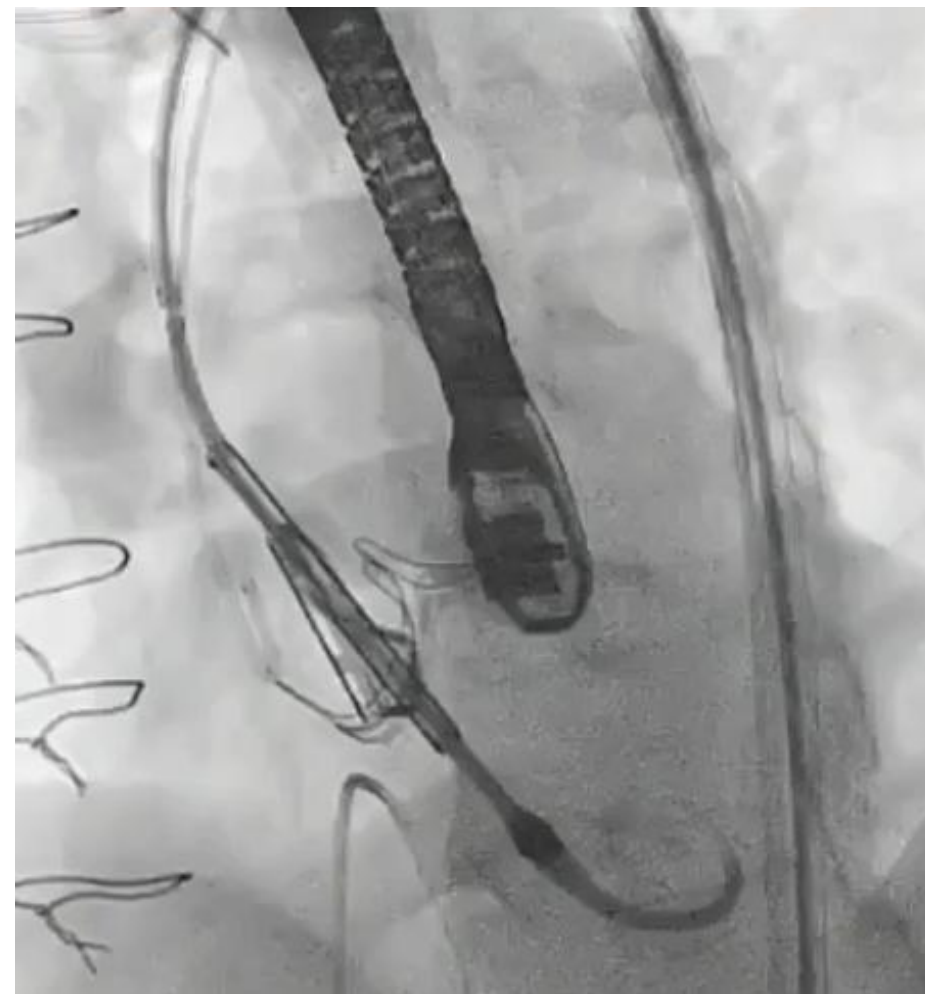
Short in Tall



Modification de feuillets/ Protection coronaire



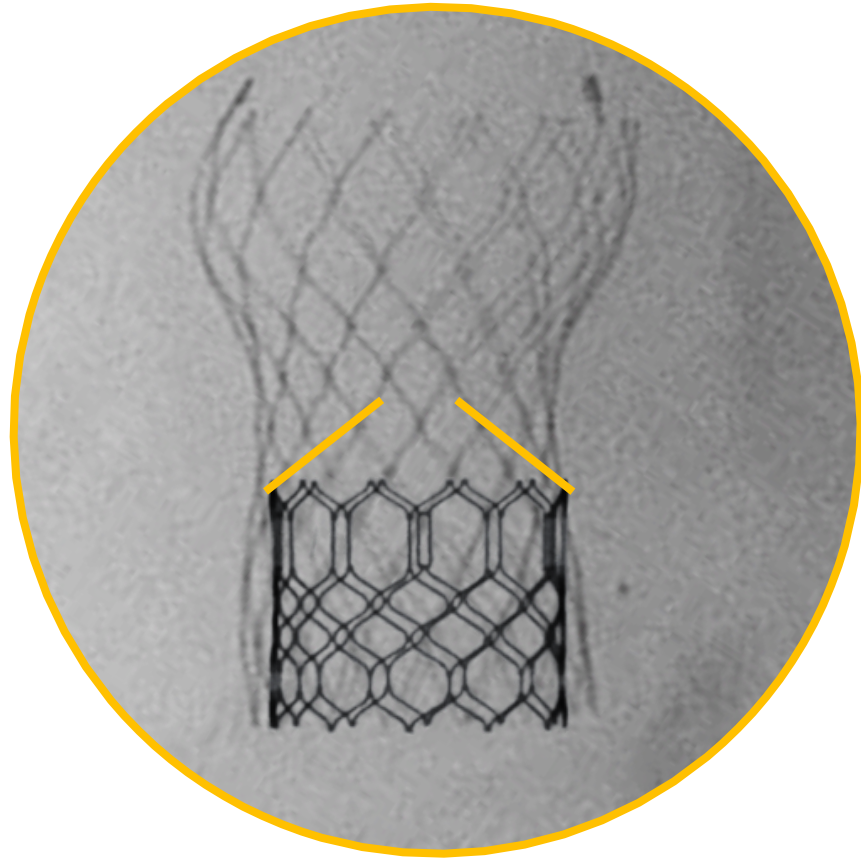


BASILICA



SHORTCUT

Leaflet overhang



Short in Tall

Redo TAVI: aspects techniques

Analyse minutieuse procédure index et CT scan

Tall in short et short in tall

Protection cérébrale

Pré et postdilatation systématiques

Prévention de l'obstruction coronaire



MERCI

THANK YOU

谢谢

EFHARISTO

DANKE

どうもありがとう

GRACIAS

תודה רבה

OBRIGADO

GRAZIE

BEDANKT

DEKUJI

Спасибо

شكرًا لك



**28-30
JANVIER
2026**

MARSEILLE
PALAIS DU PHARO

Redo TAVI: les aspects techniques

Didier TCHETCHE

